

References

11. Hamazoe R, Yoshioka H, Ikeda Y, et al. Alpha-fetoprotein-producing pancreatic carcinoma: case report and review of the Japanese literature. *Gastroenterol Jpn* 1987;22:503-8.
12. Yano T, Ishikura H, Wada T, et al. Hepatoid adenocarcinoma of the pancreas. *Histopathology* 1999;35:90-2.
13. Tanno S, Obara T, Fujii T, et al. alpha-Fetoprotein-producing adenocarcinoma of the pancreas presenting focal hepatoid differentiation. *Int J Pancreatol* 1999;26:43-7.
14. Paner GP, Thompson KS, Reyes CV. Hepatoid carcinoma of the pancreas. *Cancer* 2000;88:1582-9.
15. Lam K, Lo C, Wat M, et al. Malignant insulinoma with hepatoid differentiation: a unique case with alpha-fetoprotein production. *Endocr Pathol* 2001;12:351-4.
16. Cuilliere P, Lazure T, Bui M, et al. Solid adenoma with exclusive hepatocellular differentiation: a new variant among pancreatic benign neoplasms? *Virchows Arch* 2002;441:519-22.
17. Hirai I, Kimura W, Kamiga M, et al. Intra- and postoperative radiation therapy for an alpha-fetoprotein-producing pancreatic carcinoma. *J Hepatobiliary Pancreat Surg* 2003;10:239-44.
18. Matsueda K, Yamamoto H, Yoshida Y, et al. Hepatoid carcinoma of the pancreas producing protein induced by vitamin K absence or antagonist II (PIVKA-II) and alpha-fetoprotein (AFP). *J Gastroenterol* 2006;41:1011-9.
19. Lin YC, Lee PH, Yao YT, et al. Alpha-fetoprotein-producing pancreatic acinar cell carcinoma. *J Formos Med Assoc* 2007;106:669-72.
20. Kubota K, Kita J, Rokkaku K, et al. Ectopic hepatocellular carcinoma arising from pancreas: a case report and review of the literature. *World J Gastroenterol* 2007;13:4270-3.
21. Liu CZ, Hu SY, Wang L, et al. Hepatoid carcinoma of the pancreas: a case report. *Chin Med J (Engl)* 2007;120:1850-2.
22. Hameed O, Xu H, Saddeghi S, et al. Hepatoid carcinoma of the pancreas: a case report and literature review of a heterogeneous group of tumors. *Am J Surg Pathol* 2007;31:146-52.
23. Cardona D, Grobmyer S, Crawford JM, et al. Hepatocellular carcinoma arising from ectopic liver tissue in the pancreas. *Virchows Arch* 2007;450:225-9.
24. Jung JY, Kim YJ, Kim HM, et al. Hepatoid carcinoma of the pancreas combined with neuroendocrine carcinoma. *Gut Liver* 2010;4:98-102.
25. Kai K, Nakamura J, Ide T, et al. Hepatoid carcinoma of the pancreas penetrating into the gastric cavity: a case report and literature review. *Pathol Int* 2012;62:485-90.
26. Huang SC, Chang HC, Yeh TS, et al. Hepatoid microcarcinoma of the pancreas: a case report and review of the literature. *Chang Gung Med J* 2012;35:285-91.
27. Kelly PJ, Spence R, Dasari BV, et al. Primary hepatocellular carcinoma of the pancreas: a case report and review of the heterogeneous group of pancreatic hepatoid carcinomas. *Histopathology* 2012;60:1012-5.
28. Majumder S, Dasanu CA. Hepatoid variant of pancreatic cancer: insights from a case and literature review. *JOP* 2013;14:442-5.
29. Steen S, Wolin E, Geller SA, et al. Primary hepatocellular carcinoma ("hepatoid" carcinoma) of the pancreas: a case report and review of the literature. *Clin Case Rep* 2013;1:66-71.
30. Antonini F, Angelelli L, Rubini C, et al. Endoscopic ultrasound diagnosis of a primary hepatoid carcinoma of the pancreas. *Endoscopy* 2015;47 Suppl 1 UCTN:E367-8.
31. Veerankutty FH, Yeldho V, Tu SA, et al. Hepatoid carcinoma of the pancreas combined with serous cystadenoma: a case report and review of the literature. *Hepatobiliary Surg Nutr* 2015;4:354-62.
32. Vanoli A, Argenti F, Vinci A, et al. Hepatoid carcinoma of the pancreas with lymphoid stroma: first description of the clinical, morphological, immunohistochemical, and molecular characteristics of an unusual pancreatic carcinoma. *Virchows Arch* 2015;467:237-45.
33. Kuo PC, Chen SC, Shyr YM, et al. Hepatoid carcinoma of the pancreas. *World J Surg Oncol* 2015;13:185.
34. Zhu X, Yong H, Zhang L, et al. Pure alpha-fetoprotein-producing neuroendocrine carcinoma of the pancreas: a case report. *BMC Gastroenterol* 2015;15:16.
35. Stamatova D, Theilmann L, Spiegelberg C. A hepatoid carcinoma of the pancreatic head. *Surg Case Rep* 2016;2:78.
36. Chang JM, Katariya NN, Lam-Himlin DM, et al. Hepatoid Carcinoma of the Pancreas: Case Report, Next-Generation Tumor Profiling, and Literature Review. *Case Rep Gastroenterol* 2016;10:605-12.
37. Pellini Ferreira B, Vasquez J, Carilli A. Metastatic Hepatoid Carcinoma of the Pancreas: First Description of Treatment With Capecitabine and Temozolomide. *Am J Med Sci* 2017;353:610-2.
38. Dogeas E, Peng L, Choti MA. Hepatoid Adenocarcinoma

of Unknown Primary Masquerading as a Pancreatic Tumor. *J Gastrointest Surg* 2017;21:2132-4.

39. Fukushima K, Kobayashi A. Hepatoid carcinoma of the pancreas mimicking neuroendocrine tumor. *Hepatobiliary Surg Nutr* 2018;7:501-2.
40. Yang C, Sun L, Lai JZ, et al. Primary Hepatoid Carcinoma

of the Pancreas: A Clinicopathological Study of 3 Cases With Review of Additional 31 Cases in the Literature. *Int J Surg Pathol* 2019;27:28-42.

41. Trinh HS, Luong TH, Lai TT, et al. Mixed pancreatic hepatoid carcinoma: A surgical case report and literature review. *Int J Surg Case Rep* 2021;83:105951.

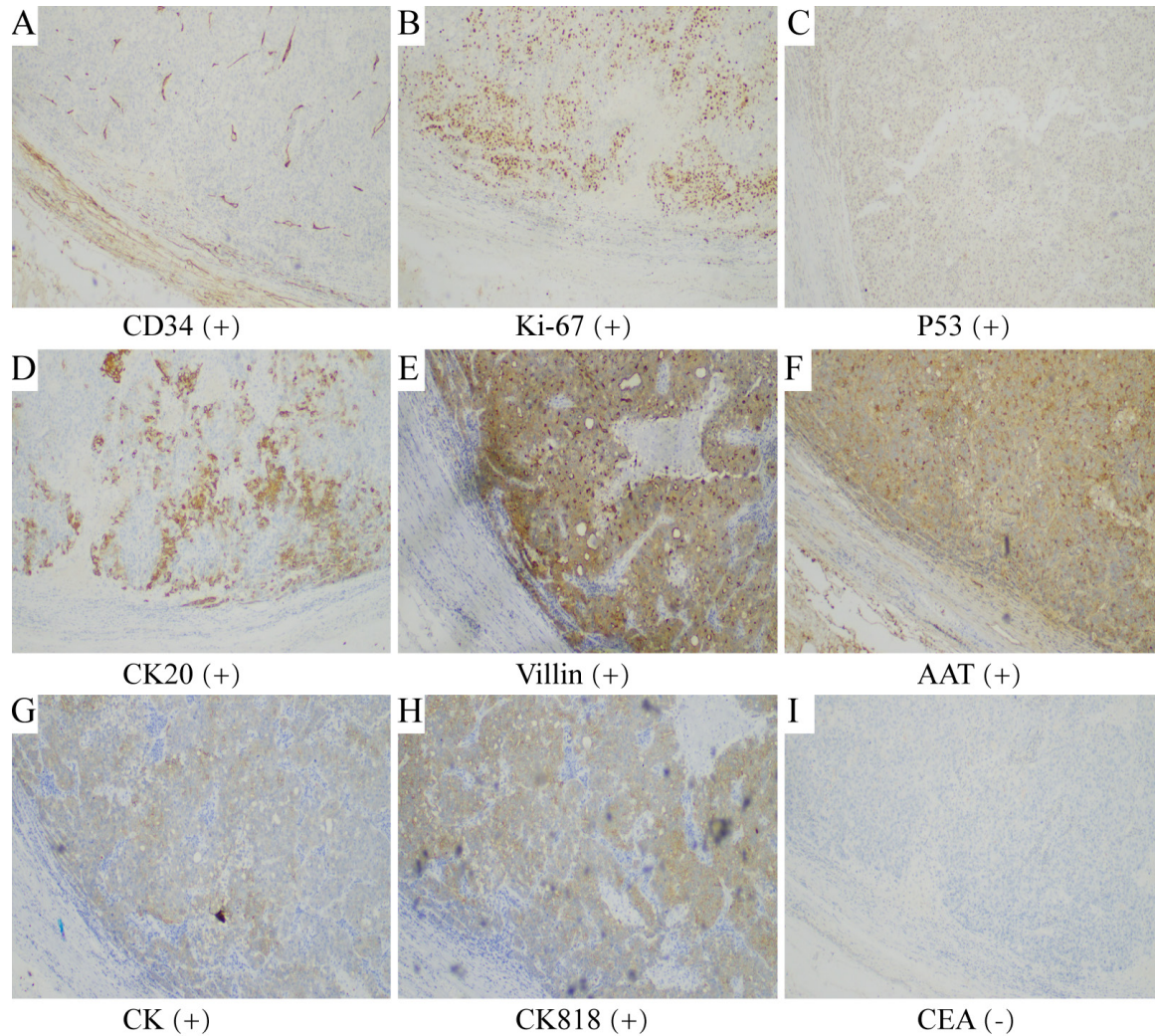


Figure S1 Immunohistochemical characteristics. (A-H) The immunohistochemical of patient tested positive for CD34, Ki-67, P53, CK20, Villin, AAT, CK, CK818. (I) The result of CEA is negative ($\times 200$). AAT, alpha 1-antitrypsin; CK, cytokeratin; CEA, carcinoembryonic antigen.

Table S1 Summary of clinical features of hepatoid carcinomas of the pancreas reported in the English language literature

Patient no.	Author/year	Age/sex	Tumor location	Tumor size (cm)	AFP value (ng/mL)	Other components	Treatment	Follow-up and outcome
1	Hamazoe <i>et al.</i> /1987 (11)	34/M	Body	ND	84,000	ND	Chemotherapy	2 months, died
2	Yano <i>et al.</i> /1999 (12)	57/M	Head	9×7×5	177.6	ND	Surgery	3 months, died
3	Tanno <i>et al.</i> /1999 (13)	65/F	Body and tail	6 cm in diameter	16,170	ND	Conservative treatment	6 months, died
4	Paner <i>et al.</i> /2000 (14)	57/M	Body and tail	6×4×3.5	ND	Glucagonoma	Surgery, chemotherapy	102 months, died
5		28/M	ND	8×8×6	ND	Ductal adenocarcinoma	Chemotherapy	14 months, died
6	Lam <i>et al.</i> /2001 (15)	64/F	Tail	4.8×2	2,119	Neuroendocrine tumor	Surgery, chemotherapy	22 months, died
7	Cuilliere <i>et al.</i> /2002 (16)	70/M	Body and tail	2.5 cm in diameter	1.9	Serous microcystic adenoma	Surgery	12 months, alive
8	Hirai <i>et al.</i> /2003 (17)	64/M	Head and body	6.5×3.5	441	ND	Surgery, radiation therapy	22 months, alive
9	Matsueda <i>et al.</i> /2006 (18)	49/F	Diffuse	ND	623	ND	Surgery	12 months, alive
10	Lin <i>et al.</i> /2007 (19)	47/M	Tail	2 cm in diameter	463.69	Acinar cell carcinoma	Surgery	36 months, alive
11	Kubota <i>et al.</i> /2007 (20)	56/M	Tail	6.5 cm in diameter	ND	ND	Surgery	36 months, alive
12	Liu <i>et al.</i> /2007 (21)	80/M	Head	4.6×4.4×5	ND	ND	Palliative surgery	8 months, alive
13	Hameed <i>et al.</i> /2007 (22)	41/F	Head	4.6×3.5	2,714	Neuroendocrine carcinoma	Surgery	26 months, died
14	Cardona <i>et al.</i> /2007 (23)	58/M	Tail	3.3×2.5×2.5	ND	ND	Surgery	15 months, alive
15	Jung <i>et al.</i> /2010 (24)	46/M	Head	7.5 cm in diameter	262.49	Neuroendocrine tumor	Surgery	4 months, alive
16	Petrelli <i>et al.</i> /2012 (9)	37/M	Body	11 cm in diameter	11	ND	Sorafenib	15 months, died
17	Kai <i>et al.</i> /2012 (25)	79/F	Tail	7×5	ND	ND	Surgery	1 months, died
18	Huang <i>et al.</i> /2012 (26)	52/M	Head	0.5 cm in diameter	ND	Neuroendocrine tumor	Surgery	11 months, alive
19	Hiraoka <i>et al.</i> /2012 (3)	25/F	Head	10 cm in diameter	1,222.40	Acinar cell carcinoma	Surgery	2 months, died
20	Kelly <i>et al.</i> /2012 (27)	53/F	Body and tail	ND	148	ND	Surgery, chemotherapy	22 months, alive
21	Majumder <i>et al.</i> /2013 (28)	60/M	Head	5.8×6	ND	ND	Chemotherapy	3 months, died
22	Steen <i>et al.</i> /2013 (29)	61/F	Tail	5 cm in diameter	4.9	ND	Surgery	60 months, alive
23	Xin <i>et al.</i> /2014 (6)	33/F	Head	2×1.4×1.8	407.5	ND	Surgery, chemotherapy, radiotherapy	46 months, alive
24	Antonini <i>et al.</i> /2015 (30)	59/M	Body	6×5	ND	ND	Sorafenib	4 months, died
25	Williams <i>et al.</i> /2015 (7)	71/M	Head	4.5 cm in diameter	0.6	ND	Surgery	ND
26	Veerankutty <i>et al.</i> /2015 (31)	47/M	Tail	2.3×2	1.75	Serous cystadenoma	Surgery	8 months, alive
27	Vanoli <i>et al.</i> /2015 (32)	57/M	Head	2.5 cm in diameter	147.8	Lymphoid stroma	Surgery, chemotherapy	18 months, alive
28	Kuo <i>et al.</i> /2015 (33)	67/M	Tail	2×2	ND	ND	Surgery	6 months, alive
29	Zhu <i>et al.</i> /2015 (34)	56/M	Body and tail	5.2×4.8×4.1	321.4	Neuroendocrine tumor	Surgery, chemotherapy	21 months, died
30	Stamatova <i>et al.</i> /2016 (35)	78/M	Head	8 cm in diameter	ND	ND	Surgery	2 months, died
31	Chang <i>et al.</i> /2016 (36)	61/M	Tail	8×5	ND	ND	Surgery	6 months, alive
32	Pellini <i>et al.</i> /2017 (37)	43/M	Tail	9 cm in diameter	2.9	Glucagonoma	Chemotherapy	16 months, alive
33	Dogear <i>et al.</i> /2017 (38)	65/M	Head	10 cm in diameter	ND	ND	Chemotherapy, surgery	ND
34	Ma <i>et al.</i> /2017 (5)	75/M	Tail	7.8 cm in diameter	1,897.70	ND	Chemotherapy, surgery	13 months, alive
35	Fukushima <i>et al.</i> /2018 (39)	44/M	Head	1.9×1.8	ND	ND	Surgery	ND
36	Yang <i>et al.</i> /2019 (40)	83/M	Body	2.7×2.5×1.5	ND	ND	Surgery	107 months, alive
37		72/M	Tail	12×10.5×4.5	ND	ND	Surgery	1 months, died
38		54/M	Body and tail	10×9×9	8,338	ND	Surgery	29 months, died
39	Wang <i>et al.</i> /2020 (2)	28/M	Head	4.2 cm in diameter	6,740.70	Neuroendocrine tumor	Chemotherapy, surgery	3 months, alive
40	Trinh <i>et al.</i> /2021 (41)	49/M	Head	2.6×2.8	2.42	Neuroendocrine tumor	Chemotherapy, surgery	8 months, alive
41	Present case	48/M	Head	7.5×7×3.7	61,887.16	ND	Surgery combined with sorafenib	27 months, alive

In the table above: 21 patients only underwent surgery without any other treatment, follow-up data of 19 cases were complete, median follow-up was 11 months and the mortality rate was 36.84%. Twelve patients underwent surgery combined with other adjuvant treatments (such as chemotherapy, radiotherapy or sorafenib), follow-up data of 11 cases were complete, median follow-up was 27 months and the mortality rate was 27.27%. Eight patients received other treatments (such as only chemotherapy, only sorafenib, palliative surgery or conservative treatment), median follow-up was 7 months and the mortality rate was 75.00%. AFP, alpha fetoprotein; M, male; ND, not described; F, female.

Table S2 Clinical and biochemical characteristics of the HCP patients

Characteristics	Number of cases (%)
Year of publication of literature	
≥2010	27 (65.9)
<2010	14 (34.1)
Age (years)	
≥60	16 (39.0)
<60	25 (61.0)
Sex	
Male	31 (75.6)
Female	10 (24.4)
Tumor location	
Head	16 (39.0)
Body	4 (9.8)
Tail	12 (29.3)
Others	9 (22.0)
AFP value (ng/mL)	
≥400	13 (31.7)
<400	12 (29.3)
ND	16 (39.0)
Other components	
Yes	15 (36.6)
No	26 (63.4)
Treatment	
Only surgery	21 (51.2)
Surgery combined with other adjuvant treatments	12 (29.3)
Others	8 (19.5)

HCP, hepatoid carcinoma of the pancreas; AFP, alpha fetoprotein; ND, not described.