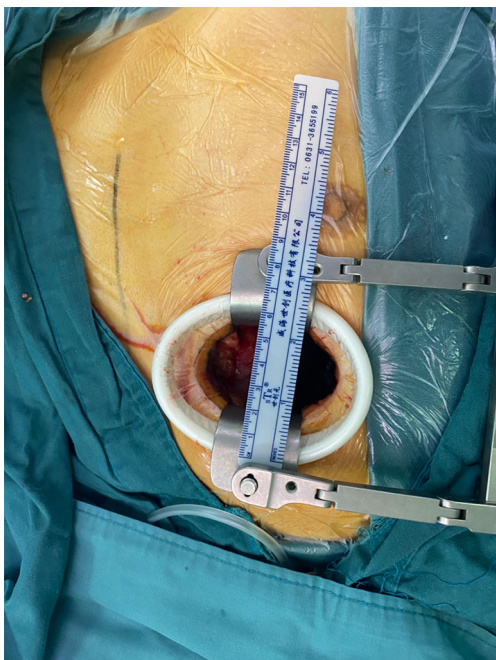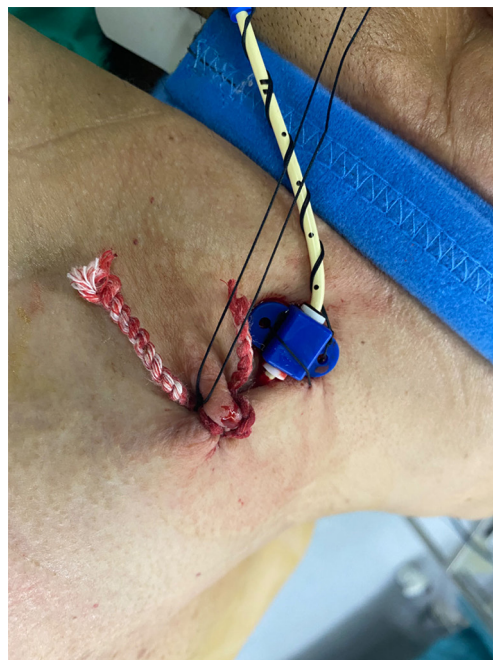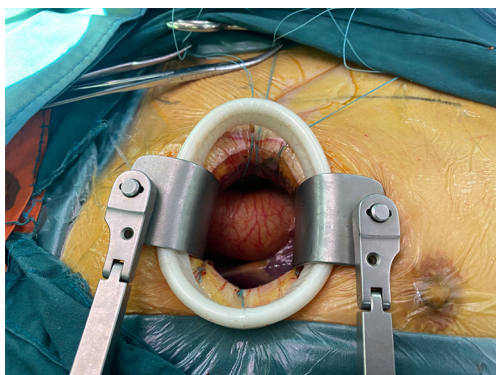


**Figure S1** Width of rib spreading.



**Figure S3** Skin incision of the right jugular cannula.



**Figure S2** Stiches of the pericardium.