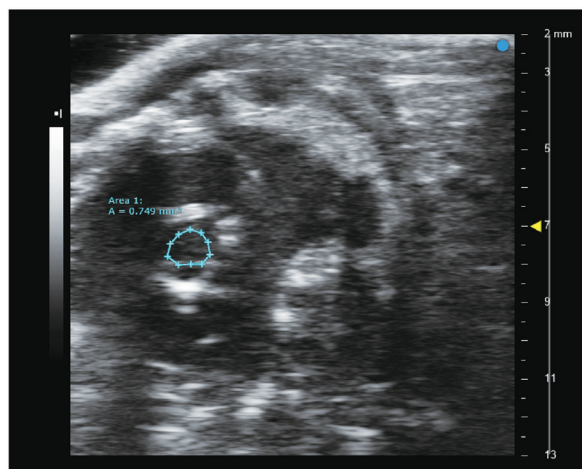


A



B

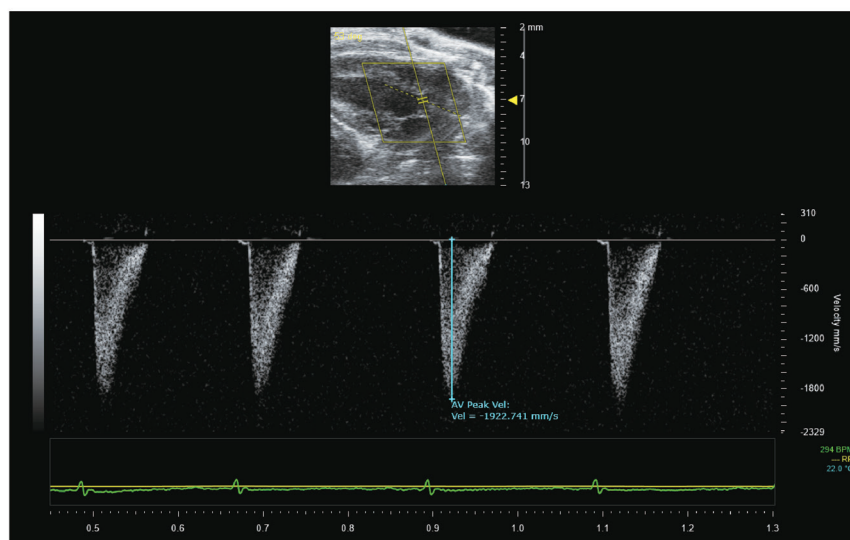


Figure S1 Echocardiography of aortic valve calcification in mice. (A) AVA measurement. The blue circle refers to the AVA. Meanwhile, the blue dot refers to the valve orifice and the yellow triangle refers to the mark point on the machine which is used to control the size of the image. (B) Peak velocity of aortic valve flow. AVA, aortic valve area.