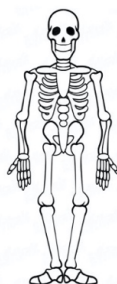




BONE MARROW ASSESSMENT REPORT BY MAGNETIC RESONANCE IMAGING



Section **BONE MARROW MRI**

- 1- ID:
- 2- DATE:
- 3- MACHINE/Sec:
- 4- THERAPY (YES / NO) Start Date:
- 5- CONTROL MRI (YES / NO)

Section	INFILTRATION	SPINE	PELVIS	FEMUR	TOTAL
6-	Homogeneous				
7-	Non homogeneous				
	• Diffuse				
	• Mottled				
	• Reticular				
8-	Non infiltration				

Section	COMPLICATIONS	SITE	TOTAL
9	Fracture		
	Infarc		
	Bone Crisis		
	Edema		
	Hemorraghe		
	AVN		
	Arthropathy		

Section	CLEARANCE	YES	NO
10	Spine		
	Pelvis		
	Femurs		

11
COMMENTS:

Figure S1 Bone marrow assessment report by magnetic resonance imaging.

Table S1 Articles related the author experience in bone marrow MRI evaluation

Roca Espiau M, Mota Martínez J.	[Present status of imaging diagnosis in type I Gaucher's disease].	Sangre (Barc).	1997	42:155-7.
Roca M, Mota J, Giraldo P, Pérez Calvo J, Gómez Pereda R, Giralto M	Magnetic resonance in the diagnosis of extent and osseous complications of Gaucher's disease type 1].	Rev Clin Esp.	1997	1978:550-4.
Roca M, Mota J, Giraldo P, García Erce JA.	Systemic mastocytosis: MRI of bone marrow involvement.	Eur Radiol.	1999	9:1094-7
Delgado P, Giraldo P, Roca M, Alvarez R.	[Magnetic resonance imaging in the early diagnosis of bone marrow necrosis].	Sangre (Barc).	1999	44:65-9.
García Erce JA, Roca Espiau M, Giraldo Castellano P	[Systemic mastocytosis and magnetic resonance].	An Med Interna	2001	18::284-5.
Poll LW, Maas M, Terk MR, Roca-Espiau M, Bembi B, Ciana G, Weinreb NJ.	Response of Gaucher bone disease to enzyme replacement therapy	Br J Radiol.	2002	75 Suppl 1:A25-36.
Wenstrup RJ, Roca-Espiau M, Weinreb NJ, Bembi B.	Skeletal aspects of Gaucher disease: a review	Br J Radiol.	2002	75 Suppl 1:A2-12.
Dobón M, Lucía JF, Aguilar C, Mayayo E, Roca M, Solano V, Peña A, Giralto M, Ferrández A	Value of magnetic resonance imaging for the diagnosis and follow-up of haemophilic arthropathy.	Haemophilia.	2003	9:76-85.
Roca M, Mota J, Alfonso P, Pocoví M, Giraldo P.	S-MRI score: A simple method for assessing bone marrow involvement in Gaucher disease	Eur J Radiol.	2007	62:132-7.
Roca Espiau M.	[Bone disease in Gaucher's disease]	Med Clin (Barc).	2011	137 Suppl 1:23-31.
Andrade-Campos M, Valero E, Roca M, Giraldo P; Spanish group on Gaucher Disease.	The utility of magnetic resonance imaging for bone involvement in Gaucher disease. Assessing more than bone crises	Blood Cells Mol Dis	2018	68:126-134