Material and methods

Histologic staining

After the micro-CT analysis, the C5 and L5samples were dissected and fixed in 4% paraformaldehyde (pH 7.4) for 48 h. Then they were dehydrated in a graded series of ethanol (EtOH) to eliminate the entire water content of these samples: starting from twice in 70% EtOH, twice in 96% EtOH, and twice in 100% ethanol in a vacuum for at least one hour in each step. After the samples were immersed in xylene for one hour, they underwent an infiltration process by placing the samples into a solution of MMA and dibutyl phthalate (6:1) for 24 h, consequently in fresh MMA, dibutyl phthalate (6:1) and 1% benzoyl peroxide solution for 24 h. Embedding of the infiltrated specimens was done in fresh MMA, dibutyl phthalate (6:1), 2.5% benzoyl peroxide solution and 1% polyethylene glycol for 24 h. Polymerization was completed within 3-5 days. However, only three samples from each group were successfully embedded. These samples were sectioned in a mid-sagittal section of thickness 200 μm by using a microtome (EXAKT E300CP, Leica Instruments, Germany), and grinded to a thickness of 150 μm with grinding machine (Mecatech334, Presi, France). One slices from each sample was selected for histologic staining. Stevenel's blue and fuchsin staining allows us to assess the presence of fibrous and bone tissue. The slices (n = 3 per group) were stained with Stevenel's blue and fuchsin staining for microscopic identification of the regions of interest (ROIs) under microscope for subsequent micro-indentation testing.

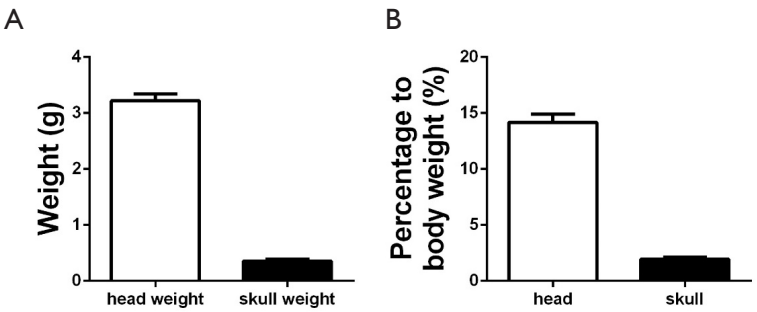

Figure S1 The weight of the head and skull of the mice, and their proportion of the body weight. Five wild type C57BL/6J mice were used, and their weight is about 25 g. (A) Weight of the head and skull of the mouse. (B) The percentage of head and skull to body weight.

https://dx.doi.org/10.21037/qims-22-717

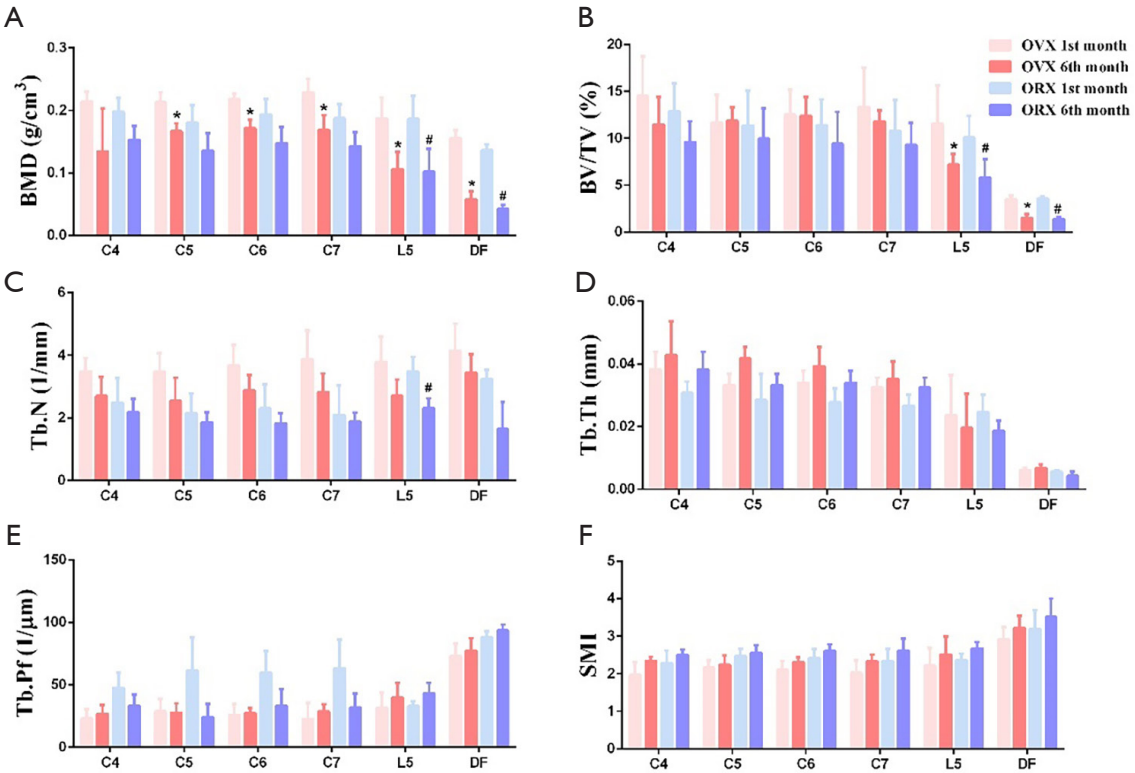

Figure S2 (A) Bone mineral density. (B) Bone volume *vs.* tissue volume. (C) Trabecular thickness. (D) Trabecular number. (E) Trabecular pattern factor. (F) Structure model index. *P<0.05 when compare to OVX first month group. #P<0.05 when compare to ORX first month group. Five mice per group were analyzed.

https://dx.doi.org/10.21037/qims-22-717



Figure S3 The exemplary 3D image from the micro-CT analysis of the different cervical vertebra and fifth lumbar from different group at first month. The female sham mice group, OVX mice group, male sham mice group and ORX mice group were shown from left to right in each column of the figure.

https://dx.doi.org/10.21037/qims-22-717

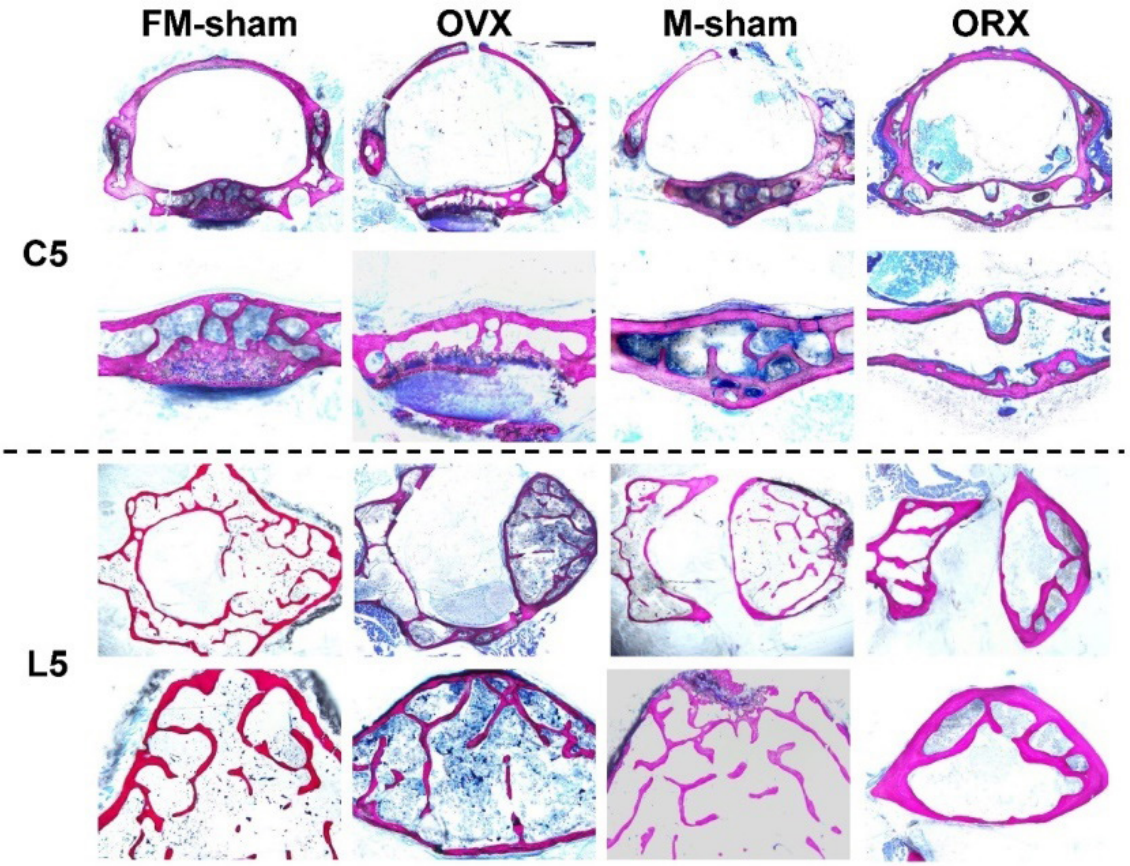

Figure S4 Stevenel's blue and fuchsin staining of the fifth cervical vertebra and fifth lumbar from different group six-month post-gonadectomy. The tissue stained with blue was the muscle and fibrocartilage. The tissue stained with red was the bone. The female sham mice group, OVX mice group, male sham mice group and ORX mice group were shown from left to right in each column of the figure.

https://dx.doi.org/10.21037/qims-22-717