

Table S1 Sociodemographic and clinical characteristics of the participants

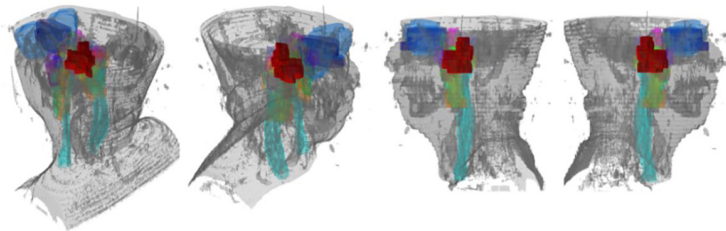
Characteristic	Total data (n=778)	5-year survival rate (%)	P
Age (years)	45 (38~53)	-	<0.001
Sex			0.357
Male	567 (72.9%)	87.52	
Female	211 (27.1%)	90.55	
Histologic type			0.136
WHO type I/II	46 (5.9%)	81.45	
WHO type III	732 (94.1%)	88.78	
EBV DNA (1,000 copy/mL)			0.001
<1	351 (45.1%)	92.95	
1-10	183 (23.5%)	83.68	
>10	244 (31.4%)	85.19	
T classification			<.001
T1	201 (25.8%)	95.61	
T2	94 (12.1%)	87.82	
T3	290 (37.3%)	90.43	
T4	193 (24.8%)	77.93	
N classification			<0.001
N0	176 (22.6%)	94.07	
N1	433 (55.7%)	89.52	
N2	111 (14.3%)	83.61	
N3	58 (7.5%)	68.22	
Staging			<0.001
I	71 (9.1%)	98.11	
II	172 (22.1%)	94.41	
III	297 (38.2%)	91.37	
IVa	238 (30.6%)	76.86	
Treatment			0.203
RT	102 (13.1%)	93.21	
CCRT	293 (37.7%)	88.09	
IC + CCRT	383 (49.2%)	87.24	

WHO, World Health Organization; EBV, Epstein-Barr virus; RT, radiotherapy; CCRT, concurrent chemoradiotherapy; IC, induction chemotherapy.

Table S2 An example of a structured VIR report for a NPC patient

Structure	Voxel number	Invasion rate (%)	Invasion: Yes/No	Location	Substructural report	Doubt
Levetor veli palatini muscle	781	23.43	√	Left		
Carotid space	41199	0.25	√	Top, left		
Lateral pterygoid muscle	12095	0				No
Longus capitis	6716	9.65	√	Top, left		
Medial pterygoid muscle	15618	0				Top near
Parapharyngeal space	21174	3.27	√	Top, left	post-styloid space and pre-styloid space	
Tenson veli palatini muscle	117	17.95	√	Left		
Base of pterygoid	1688	0				Left and rear near
Base of sphenoid	3286	46.99	√	Middle		
Clivus	4907	14.88	√	Top, middle		
Ethmoid sinus	22426	0				No
Petrous apex	2946	9.54	√	Left		
Sphenoid sinus	5892	0.48				Rear near
Cavernous sinus	3102	0				Bottom near
Orbit	56261	0				No
Trigeminal nerve	537	0				No
Foramen lacerum	1148	38.68	√	Left		
Foramen ovale	152	0				No
Foramen rotundum	152	0				No
Pterygopalatine fossa	1331	0				No

Three-dimensional structure images (tumor in red)



VIR, voxelwise invasion rate; NPC, nasopharyngeal carcinoma.