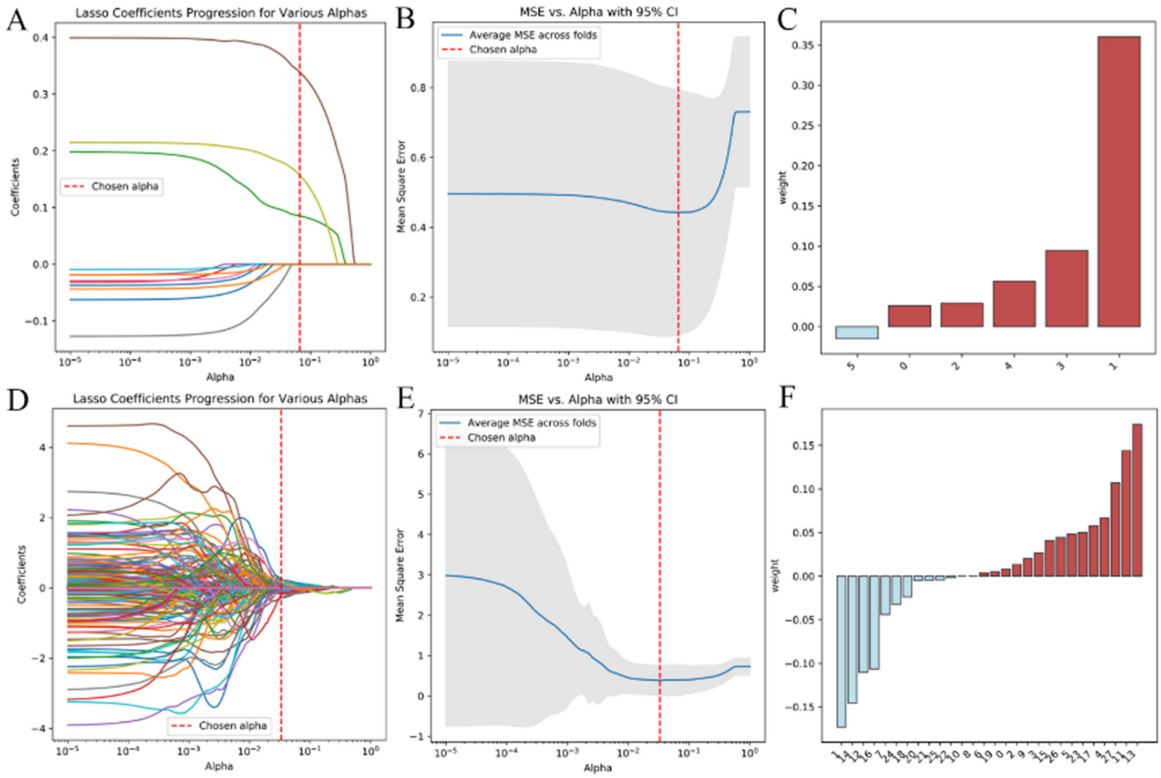

Figure S1 Image features selection using LASSO regression analysis. The LASSO regression coefficient profiles of the (A) CM features and (D) RSTD features. Cross-validation for alpha selection for the (B) CM model and (E) RSTD model. Features weights histograms of the (C) CM model and (F) RSTD model. CI, confidence interval; CM, conventional MRI; LASSO, least absolute shrinkage and selection operator; MRI, magnetic resonance imaging; MSE, mean squared error; RSTD, radiomics and Swin Transformer-based deep learning.

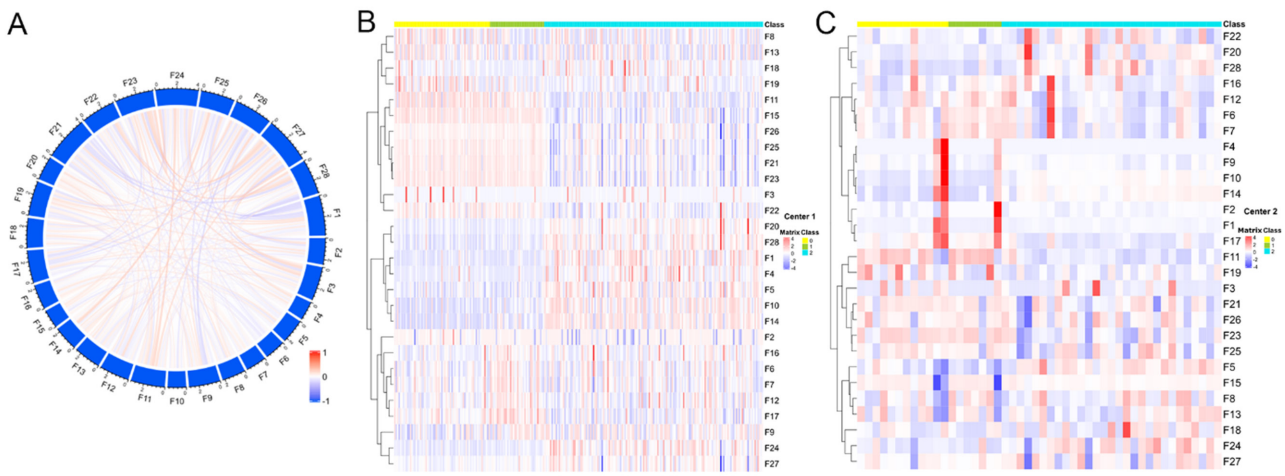

Figure S2 The heatmap of RSTD features. (A) The Person correlation of features in RSTD model showed the correlation between each feature were lower than 0.5 (P<0.05). The heatmap showed the RSTD features distribution among the three subtypes group in Center 1 (B) and Center 2 (C). Center 1, Huashan Hospital; Center 2, The First Affiliated Hospital of Anhui Medical University. Class 0, IDHmut; class 1, IDH-mutant; class 2, IDHwt. IDH, isocitrate dehydrogenase; IDHmut, astrocytoma, IDH-mutant; IDHmut-codel, oligodendroglioma, IDH-mutant and 1p/19q-codeleted; IDHwt, glioblastoma, IDH-wildtype; RSTD, radiomics and Swin Transformer-based deep learning.

https://dx.doi.org/10.21037/qims-24-2461

Table S1 MRI scan protocol in the Center 1

3.0-T MRI systems	Sequences	TR (ms)	TE (ms)	Section thickness (mm)	Intersection gap (mm)	FOV (mm)	Matrix	b value (s/mm^2)
Siemens Prisma	T1WI	1,100–1,400	8.5–10	5	5	180×240	256×163	–
	T2WI	3,180–5,000	99–101	5	5	180×240	320×216	–
	FLAIR	7,500–8,000	79–86	5	5	195×240	320×182	–
	DWI	1,600–2,400	67	5	5	220×220	192×192	0, 1,000
	3D T1C	1,700	2.45	1	0	250×250	256×256	–
Siemens Verio	T1WI	2,000	17	5	5	200×230	256×256	–
	T2WI	3,100–3,500	95–99	5	5	200×230	256×256	–
	FLAIR	8,000–9,000	94–102	5	5	200×230	190×250	–
	DWI	4,900–5,000	76–104	5	5	230×230	192×192	0, 1,000
	3D T1C	1,600–2,500	2.93	1	0	200×250	200×256	–
GE Discovery 750	T1WI	1,750–2,385	22–24	5	5	240×240	288×288	–
	T2WI	43,000	90	5	5	240×240	256×256	–
	FLAIR	8,000–8,525	140–146	5	5	240×240	256×224	–
	DWI	3,000	65	5	5	240×240	256×256	0, 1,000
	3D T1C	1,850–1,871	21–24	1	0	240×240	288×288	–
GE Discovery 750W	T1WI	1,725–1,750	7.5–26	5	5	240×240	192×256	–
	T2WI	3,872–4,840	102–103	5	5	240×240	192×256	–
	FLAIR	6,600–9,000	89–98	5	5	240×240	192×256	–
	DWI	3,228–4,600	77–80	5	5	240×240	192×256	0, 1,000
	3D T1C	1,656–1,750	20–27	1	0	256×256	192×256	–

Center 1, Huashan Hospital. 3D T1C, three-dimensional contrast-enhanced T1-weighted; DWI, diffusion-weighted imaging; FLAIR, fluid-attenuated inversion recovery; FOV, field of view; MRI, magnetic resonance imaging; T1WI, T1-weighted image; T2WI, T2-weighted image; TE, echo time; TR, repetition time.

https://dx.doi.org/10.21037/qims-24-2461

Table S2 MRI scan protocol in the Center 2

3.0-T MRI systems	Sequences	TR (ms)	TE (ms)	Section thickness (mm)	Intersection gap (mm)	FOV (mm)	Matrix	b value (s/mm^2)
Philips Ingenia	T1WI	2,000	15	6	6	240×240	232×170	–
	T2WI	2,501–3,500	105–115	6	6	240×240	256×256	–
	FLAIR	6,000	120	6	6	240×240	240×181	–
	DWI	2,688–2,711	84–86	6	6	240×240	152×106	0, 1,000
	3D T1C	7	3	1	1	240×240	244×232	–
GE Signa HDxt	T1WI	1,972–2,287	22–26	5	5	198×198	320×224	–
	T2WI	4,480	117–119	5	5	187×187	384×256	–
	FLAIR	9,002	152–155	5	5	220×220	320×192	–
	DWI	5,600	75–76	5	5	220×220	160×160	0, 1,000
	3D T1C	7	3	1	0	220×220	256×256	–
GE Discovery 750W	T1WI	1,792–2,242	22	5	5	192×192	320×224	–
	T2WI	4,253–6,772	101–128	5	5	192×192	384×224	–
	FLAIR	9,000	118–120	5	5	192×192	256×224	–
	DWI	4,880	77–78	5	5	240×240	130×160	0, 1,000
	3D T1C	7–8	3	1	0	208×208	256×160	–

Center 2, The First Affiliated Hospital of Anhui Medical University. 3D T1C, three-dimensional contrast-enhanced T1-weighted; DWI, diffusion-weighted imaging; FLAIR, fluid-attenuated inversion recovery; FOV, field of view; MRI, magnetic resonance imaging; T1WI, T1-weighted image; T2WI, T2-weighted image; TE, echo time; TR, repetition time.

https://dx.doi.org/10.21037/qims-24-2461

Table S3 CM features assessment according to VASARI

MRI features	Category	Definition
1. Tumor location	Frontal, temporal, insular, parietal, occipital, others (corpus callosum, basal ganglia, thalamus, brainstem, cerebellum)	Location of lesion geographic epicenter; the largest component of the tumor (either contrast-enhancing tumor or non-enhancing tumor)
2. Tumor size	Centimeter	The longest diameter of the tumor (with both CET and nCET, without edema)
3. Tumor margin	Clear or indistinct	The margin of the surrounding non-enhancing high-signal intensity on FLAIR was recorded as clear or indistinct
4. Enhancement quality	None, mild/minimal, marked/avid	No enhancement. Mild/minimal, barely discernable degree of enhancement relative to pre-contrast images. Marked/avid, Obvious tissue enhancement
5. Proportion enhancing	None, <30%, 30–59%, ≥60%	Proportion of enhancing tumor estimated in the entire tumor volume
6. Proportion necrosis	None, <30%, 30–59%, ≥60%	Proportion of necrosis estimated in the entire tumor volume Necrosis is defined as a region within the tumor that does not enhance or shows markedly diminished enhancement, is high on T2WI, is low on T1WI, and has an irregular border
7. Cyst	Positive or negative	Presence of well defined, rounded regions of very bright T2 signal and low T1 signal essentially matching CSF signal intensity, with very thin, regular, nonenhancing or regularly enhancing walls
8. Multifocal	None, multifocal, multicentric	Multifocal is defined as having at least one region of tumor, either enhancing or nonenhancing, which is not contiguous with the dominant lesion and is outside the region of signal abnormality (edema) surrounding the dominant mass. Multicentric are widely separated lesions in different lobes or different hemispheres that cannot be attributed to one of the previously mentioned pathways
9. T1/FLAIR ratio	Expansive, mixed, infiltrative	Expansive, size of pre-contrast T1 abnormality (exclusive of signal intensity) approximates size of FLAIR abnormality. Mixed, size of T1 abnormality moderately less than FLAIR envelope. Infiltrative, size of pre-contrast T1 abnormality much smaller than size of FLAIR abnormality
10. T2/FLAIR mismatch	Positive or negative	Presence or absence of complete/near-complete hyperintense signal on T2WI, and relatively hypointense signal on FLAIR except for a hyperintense peripheral rim
11. Thickness of enhancing margin	Thin (<3 mm), thick/nodular (≥3 mm), solid	Most of the enhancing rim is thin, regular, and measures <3 mm in thickness and has homogenous enhancement the grade is thin. Most of the rim demonstrates nodular and/or thick enhancement. There is only solid enhancement and no rim, the grade is solid
12. Proportion of edema	None, mild, obvious	No edema. Mild, the maximal diameter of edema < tumor. Obvious, the maximal diameter of edema ≥ tumor
13. Hemorrhage	Positive or negative	Intrinsic hemorrhage in the tumor matrix. Any intrinsic foci of low signal on T2WI or high signal on T1WI (use B0 image if necessary for confirmation)
14. Pial invasion	Positive or negative	Enhancement of the overlying pia in continuity with enhancing or non-enhancing tumor
15. Ependymal extension	Positive or negative	Invasion of any adjacent ependymal surface in continuity with enhancing or non-enhancing tumor matrix
16. Cortical involvement	Positive or negative	Contrast-enhancing tumor or nonenhancing tumor extending to the cortical mantle, or cortex is no longer distinguishable relative to subjacent tumor
17. Deep white matter invasion	Positive or negative	Enhancing or nCET tumor extending into the internal capsule, corpus callosum or brainstem
18. Crosses midline	Positive or negative	Enhancing tissue or nCET crosses into contralateral hemisphere through white matter commissures (exclusive of herniated ipsilateral tissue)
19. Satellites	Positive or negative	A satellite lesion is an area of enhancement within the region of signal abnormality surrounding the dominant lesion but not contiguous in any part with the major tumor mass
20. Restricted diffusion	Positive or negative	Restricted diffusion (high signal on DWI and low signal on ADC map) in the enhancing or nCET portion of the tumor

Details of qualitative imaging analyses can be seen on the following site: https://wiki.cancerimagingarchive.net/display/Public/VASARI+Research+Project. CET, contrast-enhancing tumor; CM, conventional MRI; CSF, cerebrospinal fluid; DWI, diffusion-weighted imaging; FLAIR, fluid-attenuated inversion recovery; MRI, magnetic resonance imaging; nCET, non-CET; T1WI, T1-weighted image; T2WI, T2-weighted image; VASARI, Visually Accessible Rembrandt Images.

https://dx.doi.org/10.21037/qims-24-2461

Table S4 The hyperparameter optimization of ML algorithms in model development

ML model	Best model parameters		
	CM model	RSTD model	Combined model
kNN	Algorithm: kd_tree, n_neighbors: 3, weights: distance	Algorithm: kd_tree, n_neighbors: 1, weights: uniform	Algorithm: auto, n_neighbors: 8, weights: distance
LightGBM	Learning_rate: 0.321, max_depth: 1, n_estimators: 5	Learning_rate: 0.436, max_depth: 7, n_estimators: 47	Learning_rate: 0.126, max_depth: 9, n_estimators: 8
RF	Max_depth: 2, min_samples_split: 4, n_estimators: 38	Max_depth: 4, min_samples_split: 4, n_estimators: 46	Max_depth: 4, min_samples_split: 9, n_estimators: 16
SVM	C: 1.0, kernel: rbf, gamma: auto	C: 1.0, kernel: kernel, gamma: auto	C: 1.0, kernel: rbf, gamma: auto
SGD	Alpha: 0.01, loss: log_loss, penalty: 12	Alpha: 0.01, loss: log_loss, penalty: 12	Alpha: 0.01, loss: log_loss, penalty: 12
XGBoost	N_estimators: 26, max_depth: 3, learning_rate: 0.243	N_estimators: 32, max_depth: 3, learning_rate: 0.376	N_estimators: 40, max_depth: 1, learning_rate: 0.441

The GPU system used in this study is the NVIDIA Tesla P40, which has 22.5 GB of dedicated memory. CM, conventional MRI; kNN, k-nearest neighbor; LightGBM, light gradient-boosting machine; ML, machine learning; MRI, magnetic resonance imaging; RF, random forest; RSTD, radiomics and Swin Transformer-based deep learning; SGD, stochastic gradient descent; SVM, support vector machine; XGBoost, extreme gradient boosting.

https://dx.doi.org/10.21037/qims-24-2461

Table S5 Selected features for the CM and RSTD models

Model	Name	Feature
CM model (6 features)	Location	Tumor location
	Equality	Enhancement quality
	Eproportion	Proportion enhancing
	Ethickness	Thickness of enhancing margin
	EpendymalExtension	Ependymal extension
	CorticalInvolvement	Cortical involvement
RSTD model (28 features)	Radiomics features	
	F1	Original_firstorder_MeanAbsoluteDeviation
	F2	Original_glcm_ClusterShade
	F3	Original_ngtdm_Contrast
	F4	Log-sigma-1-mm-3D_firstorder_TotalEnergy
	F5	Log-sigma-1-mm-3D_glrlm_LongRunLowGrayLevelEmphasis
	F6	Log-sigma-1-mm-3D_glrlm_RunLengthNonUniformityNormalized
	F7	Log-sigma-1-mm-3D_glrlm_ShortRunEmphasis
	F8	Log-sigma-1-mm-3D_glszm_GrayLevelNonUniformityNormalized
	F9	Log-sigma-1-mm-3D_glszm_GrayLevelVariance
	F10	Log-sigma-1-mm-3D_glszm_HighGrayLevelZoneEmphasis
	F11	Log-sigma-1-mm-3D_glszm_LowGrayLevelZoneEmphasis
	F12	Log-sigma-2-mm-3D_glrlm_ShortRunEmphasis
	F13	Log-sigma-2-mm-3D_glszm_GrayLevelNonUniformityNormalized
	F14	Log-sigma-2-mm-3D_glszm_HighGrayLevelZoneEmphasis
	F15	Log-sigma-3-mm-3D_firstorder_10Percentile
	F16	Log-sigma-3-mm-3D_glrlm_RunLengthNonUniformityNormalized
	F17	Log-sigma-3-mm-3D_glrlm_ShortRunHighGrayLevelEmphasis
	F18	Log-sigma-3-mm-3D_glszm_SizeZoneNonUniformity
	F19	Log-sigma-3-mm-3D_glszm_SmallAreaLowGrayLevelEmphasis
	Swin Transformer-based deep learning features	
	F20	Column_97
	F21	Column_134
	F22	Column_217
	F23	Column_434
	F24	Column_460
	F25	Column_655
	F26	Column_895
	F27	Column_998
	F28	Column_1003

CM, conventional MRI; MRI, magnetic resonance imaging; RSTD, radiomics and Swin Transformer-based deep learning.

https://dx.doi.org/10.21037/qims-24-2461