

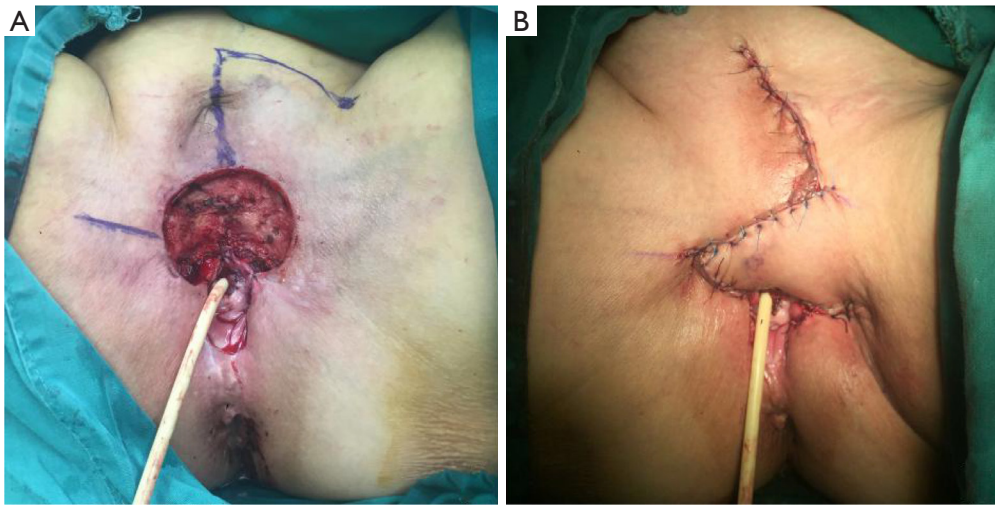Figure S1 Female, 73 Y. (A)The size of the wound after vulvar squamous cell carcinoma expansion is 5 cm × 4.5 cm. Design of a rhomboid flap, 6 cm × 5 cm. (B) The flap completely covers the wound.

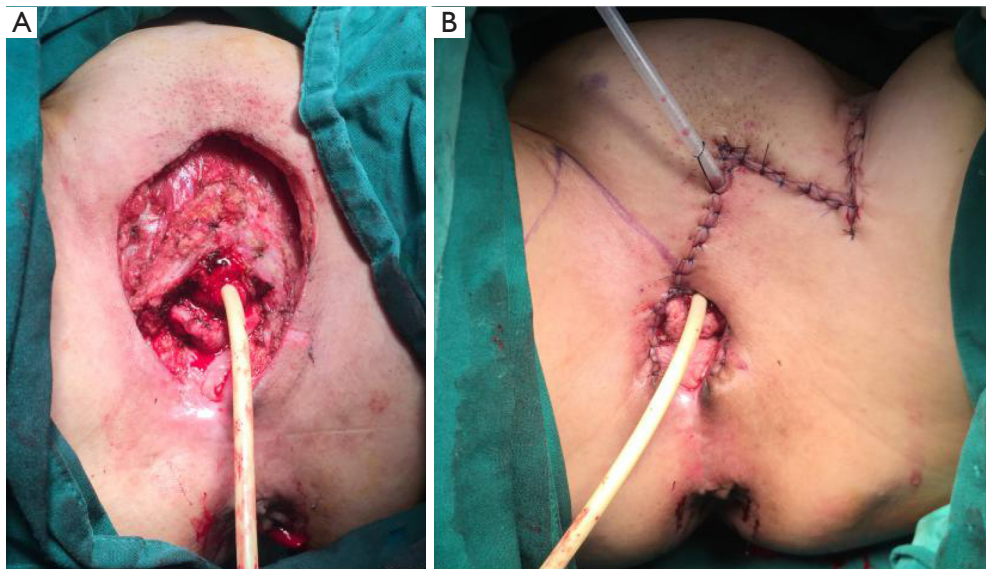


Figure S2 Female, 65 Y. (A)The size of the wound after vulvar squamous cell carcinoma expansion is 7.5 cm × 6 cm. Design of a rhomboid flap, 8 cm × 6 cm. (B) The flap completely covers the wound.

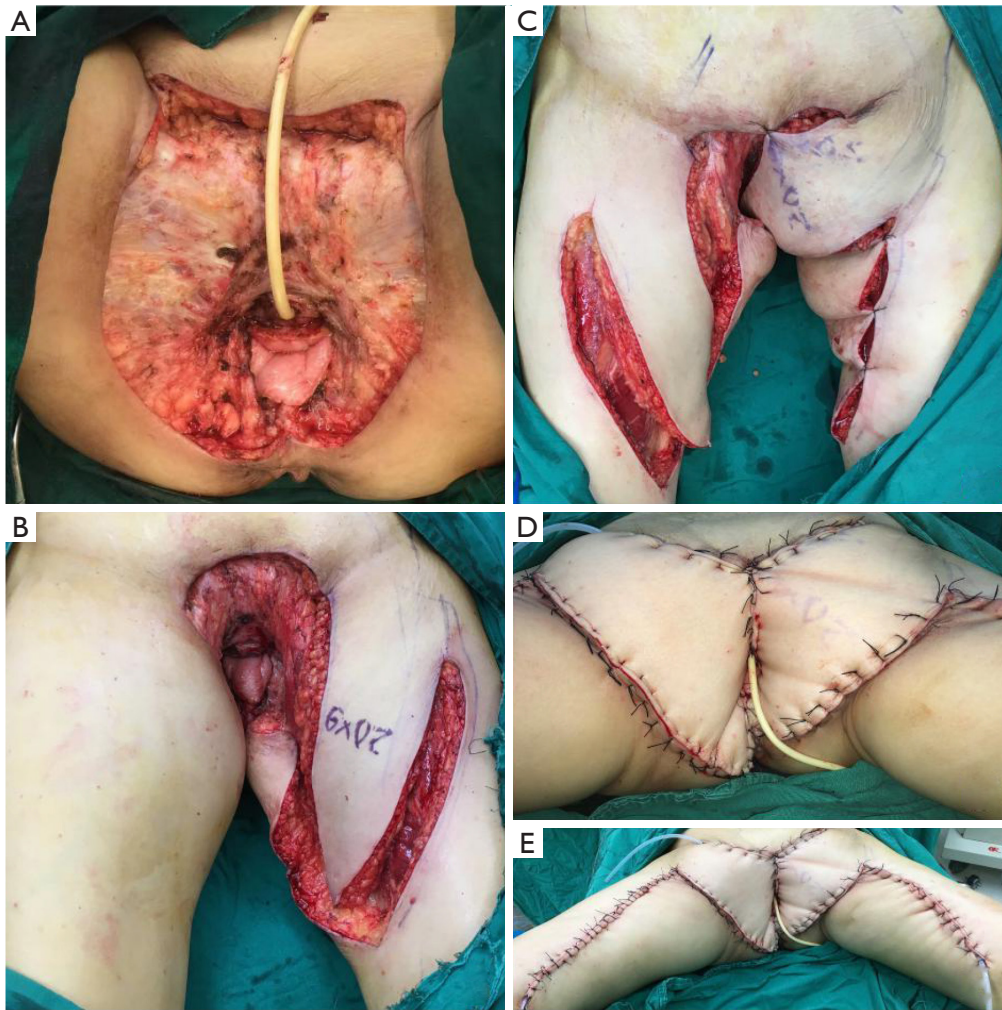


Figure S3 Female, 65 Y. (A)The size of the wound after vulvar squamous cell carcinoma expansion is 18 cm × 16 cm. (B,C) Design of a medial femoral flap, left 20 cm × 9 cm + right 25 cm × 8 cm. (D,E) The flap completely covers the wound.

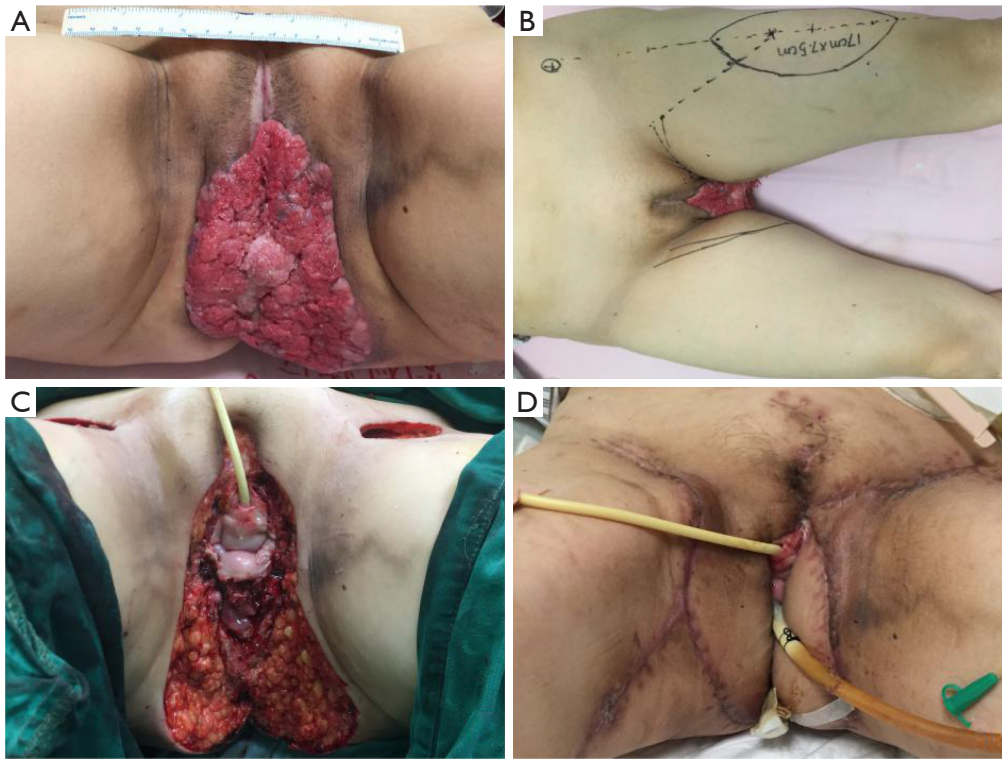


Figure S4 Female, 55 Y. (A,C)The size of the wound after vulvar squamous cell carcinoma expansion is 14 cm × 14 cm. (B) Design of a right medial femoral flap 16 cm × 8 cm + left anterolateral thigh flap 17 cm × 7.5 cm. The flap completely covers the wound. (D) Two weeks after surgery.

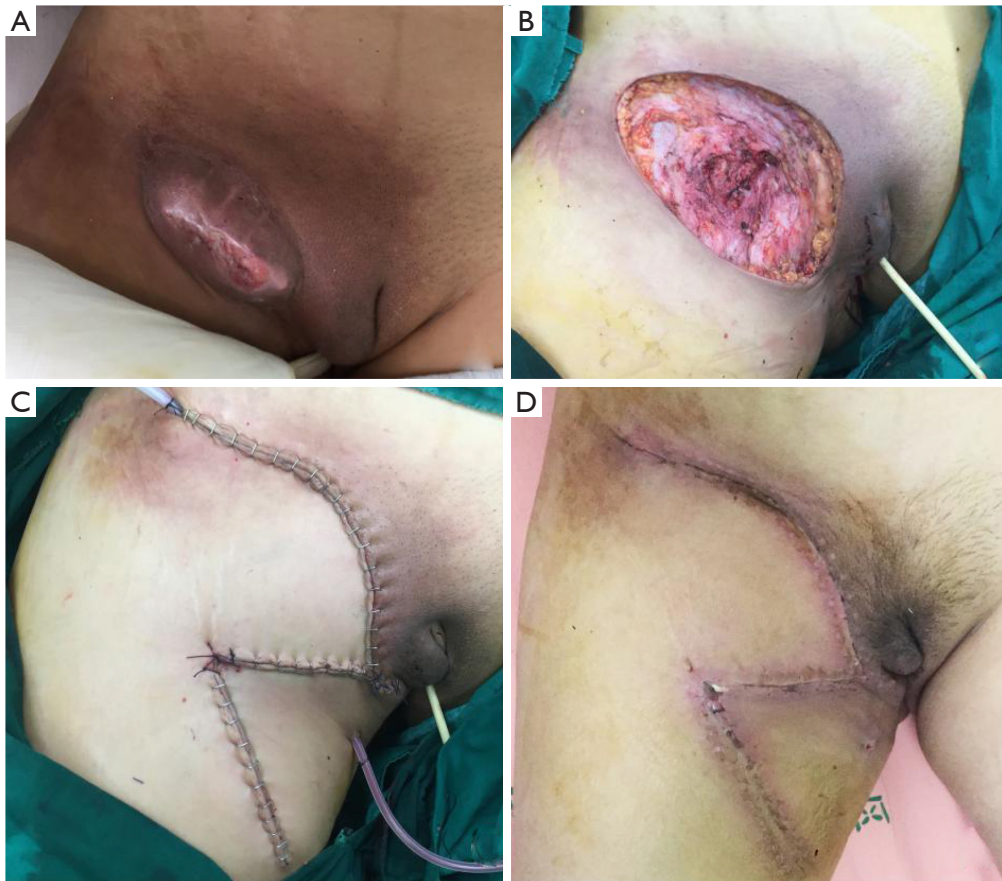


Figure S5 Female, 73 Y. (A)The size of the wound after vulvar squamous cell carcinoma expansion is 13 cm × 8 cm. (B) Design of a rhomboid flap, 13 cm × 8 cm. (C) The flap completely covers the wound. (D) Two weeks after surgery.

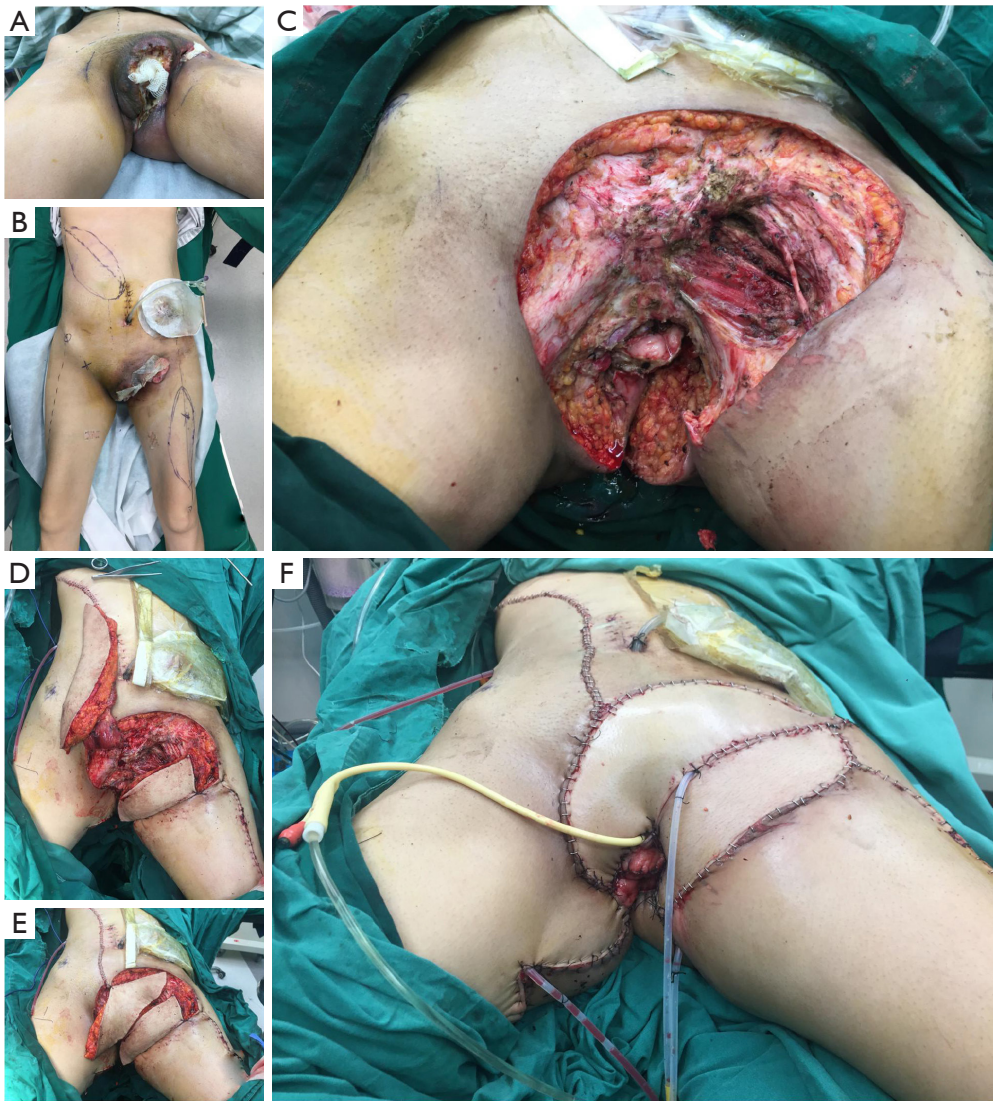

Figure S6 Female, 53 Y. (A,C)The size of the wound after vulvar squamous cell carcinoma expansion is 26 cm × 10 cm. (B,D,E) Design of a right VRAM flap 26 cm × 5 cm + left anterolateral thigh flap 7 cm × 6 cm. (F) The flap completely covers the wound. VRAM: Vertical rectus abdominis myocutaneous flap.

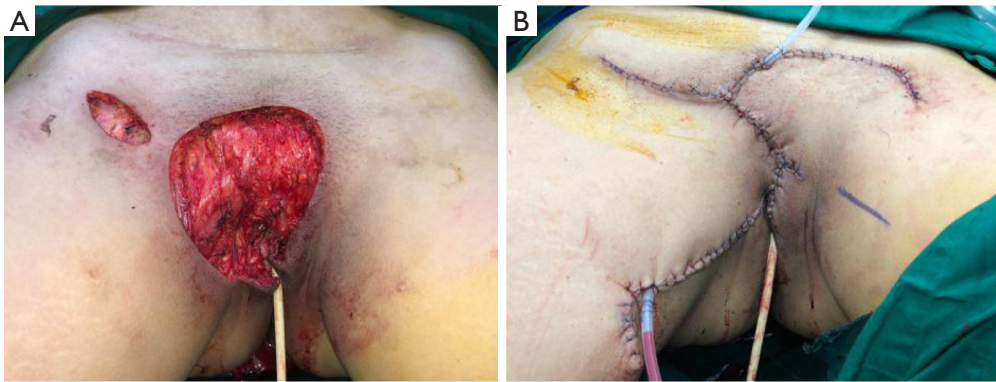


Figure S7 Female, 40 Y. (A)The size of the wound after dermatofibrosarcoma protuberans expansion is 9 cm × 5 cm. Design of a rhomboid flap, 10 cm × 5 cm. (B) The flap completely covers the wound.

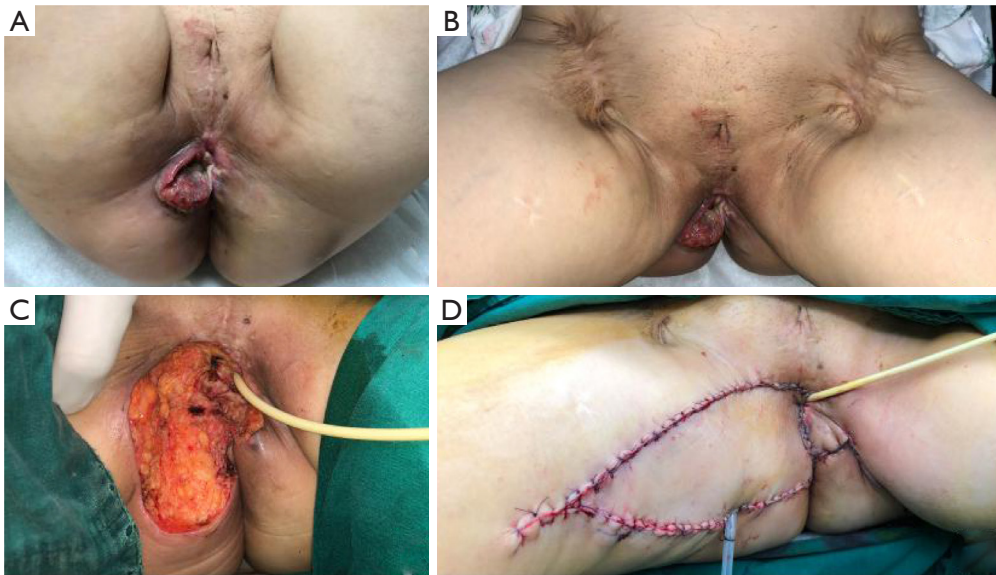


Figure S8 Female, 61 Y. (A,B)The size of the wound after vulvar squamous cell carcinoma expansion is 15 cm × 15 cm. (C) Design of a V-Y flap, right 15 cm × 15 cm + left 4 cm × 4 cm. (D) The flap completely covers the wound.

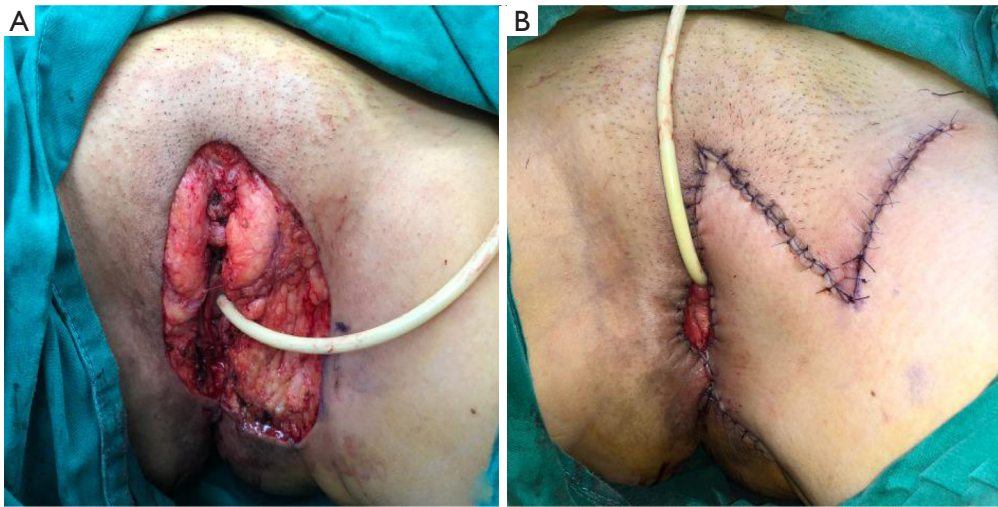


Figure S9 Female, 62 Y. (A)The size of the wound after Paget's disease expansion is 5 cm × 4 cm. Design of a rhomboid flap, 5 cm × 4 cm. (B) The flap completely covers the wound.

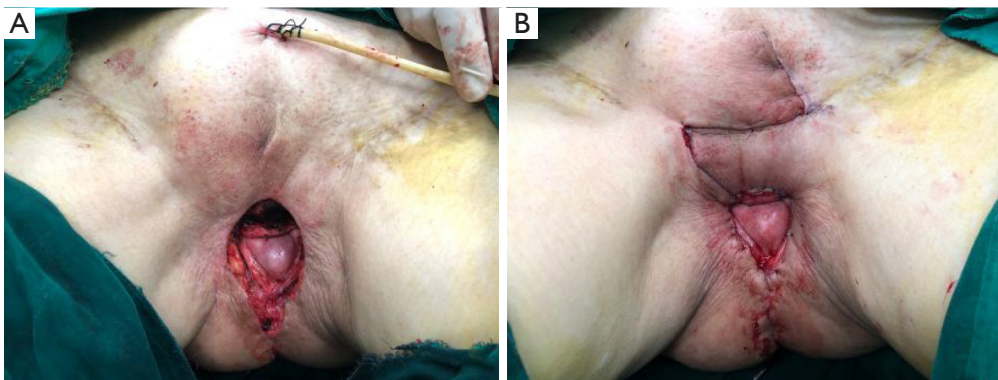


Figure S10 Female, 72 Y. (A)The size of the wound after vulvar squamous cell carcinoma expansion is 4.5 cm × 2.4 cm. Design of a rhomboid flap, 5 cm × 3 cm. (B) The flap completely covers the wound.

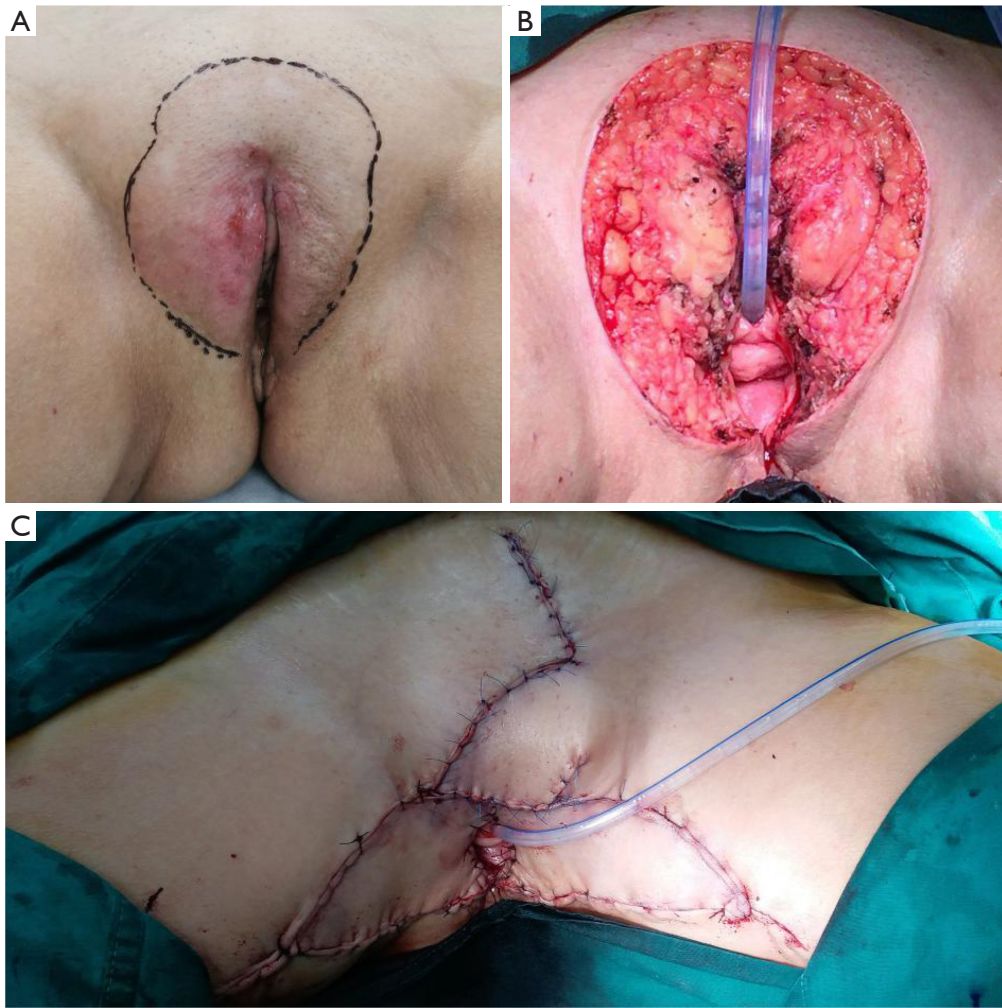


Figure S11 Female, 73 Y. (A)The size of the wound after Paget's disease expansion is 12 cm × 10 cm. (B) Design of a V-Y flap 9 cm × 7 cm + modified rhomboid flap 5 cm × 3 cm. (C) The flap completely covers the wound.

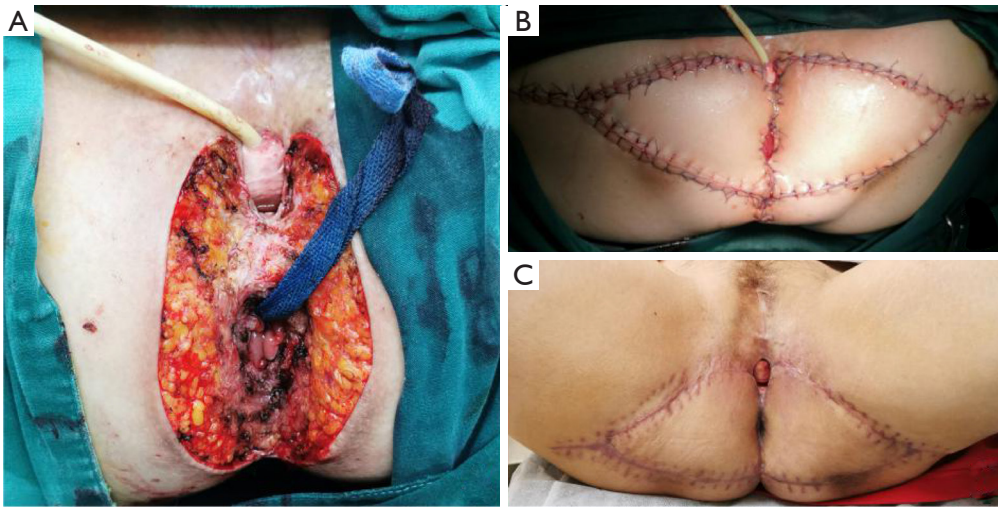


Figure S12 Female, 54 Y. (A)The size of the wound after vulvar squamous cell carcinoma expansion is 10 cm × 7 cm. (B) Design of a bilateral V-Y flap, 10 cm × 7 cm + 10 cm × 7 cm. The flap completely covers the wound. (C) Two weeks after surgery.