

Figure S1 Representative picture shows intratumoral region and peritumoral region in primary tracheobronchial neoplasm. (Immunohistochemical staining for CD8+ cells; Black line: the boundary between intratumoral region and peritumoral region; Black arrow: CD8+ cell).

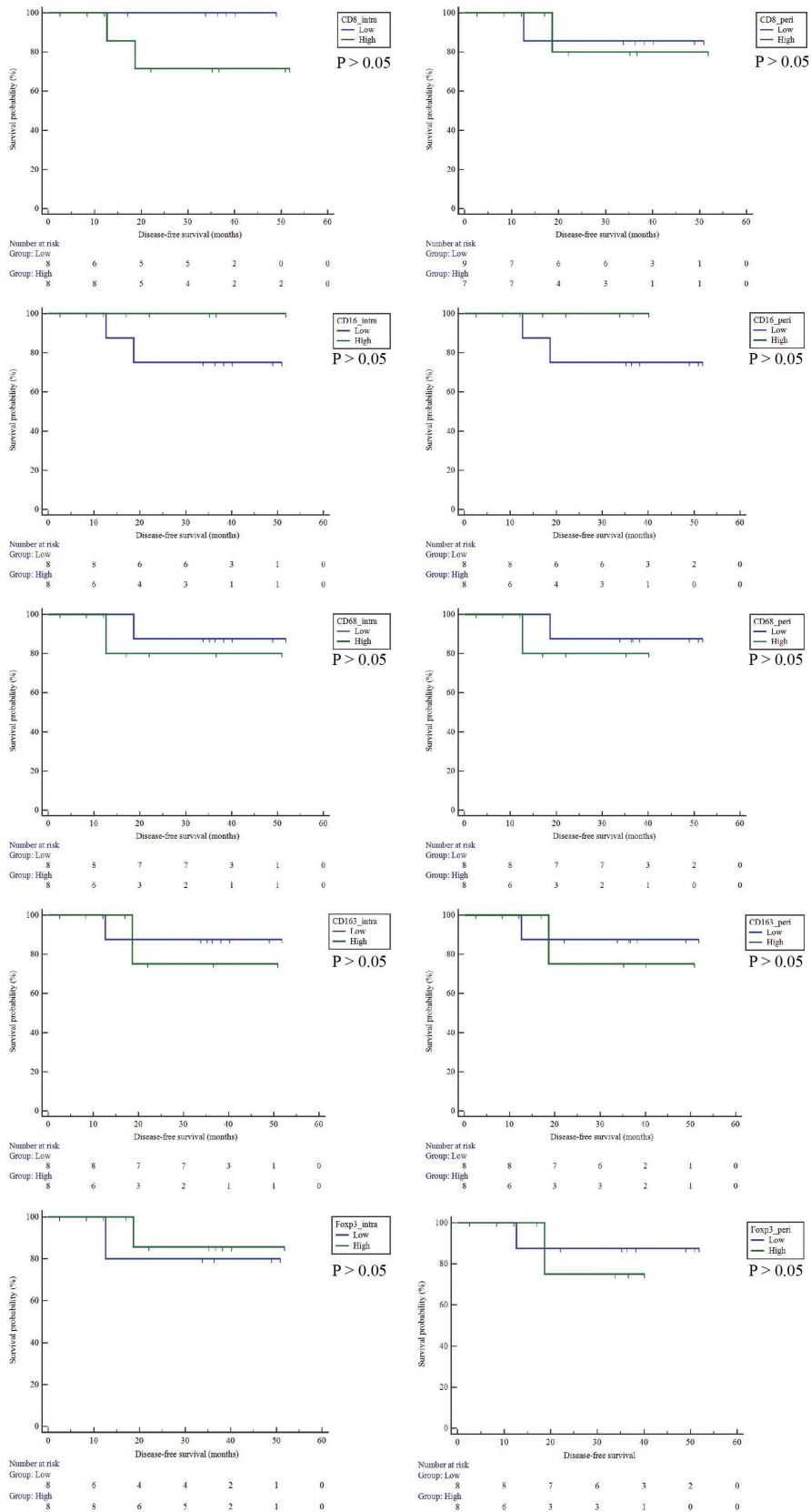


Figure S2 The relationship between the infiltration of immune cells and disease-free survival in ACC. ACC, adenoid cystic carcinoma.

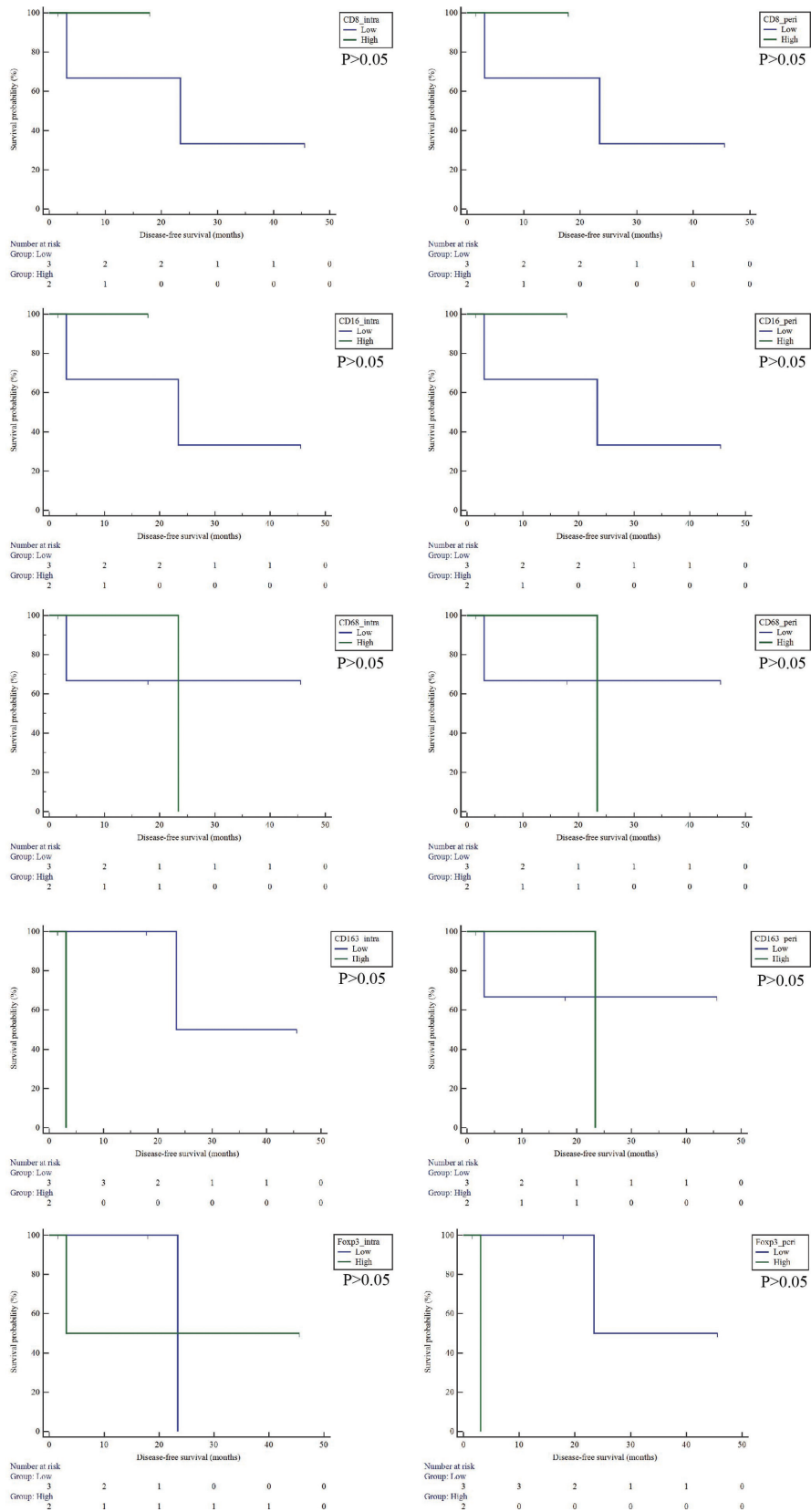


Figure S3 The relationship between the infiltration of immune cells and disease-free survival in SCC. SCC, squamous cell carcinoma.

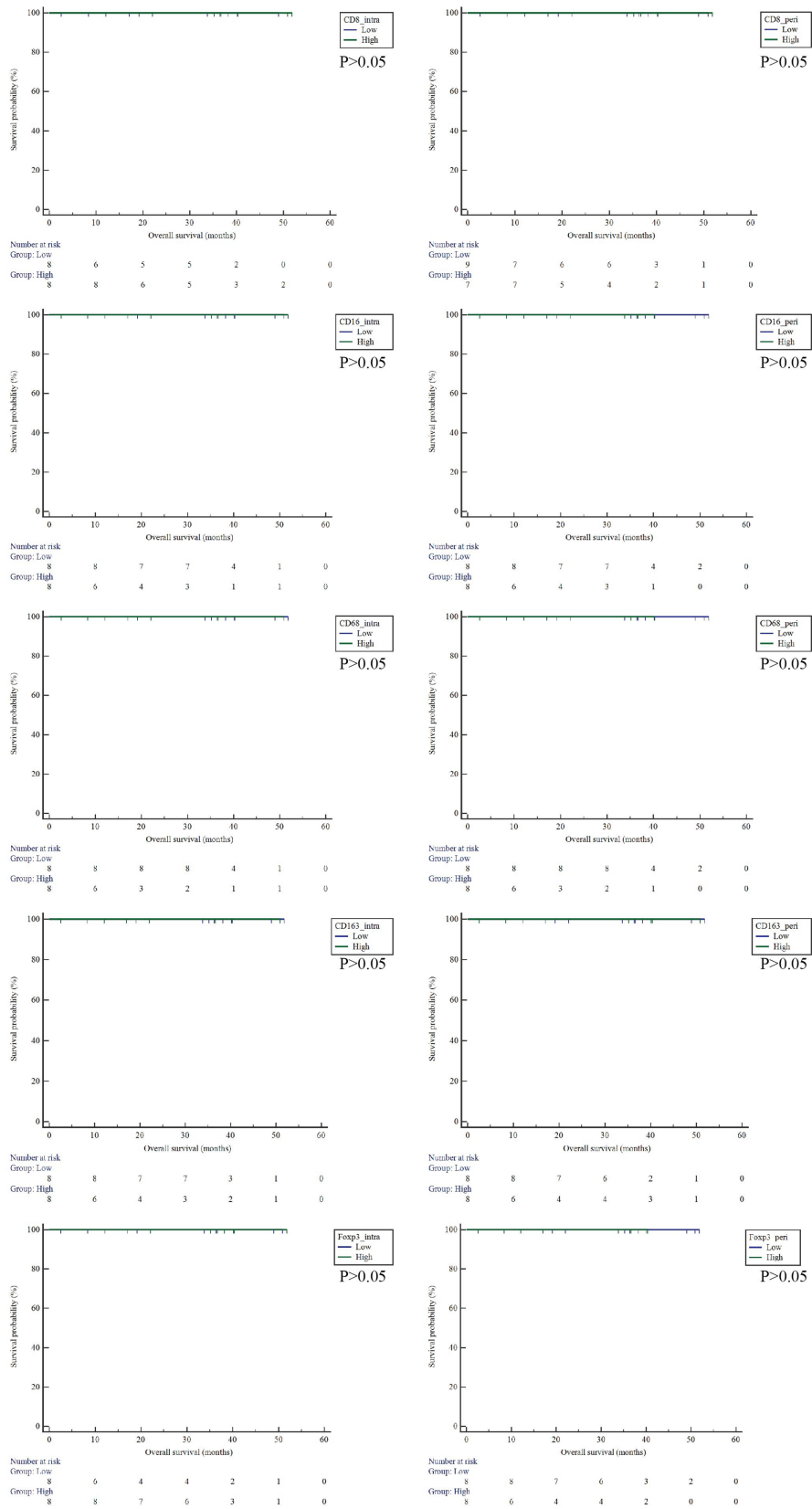


Figure S4 The relationship between the infiltration of immune cells and overall survival in ACC. ACC, adenoid cystic carcinoma.

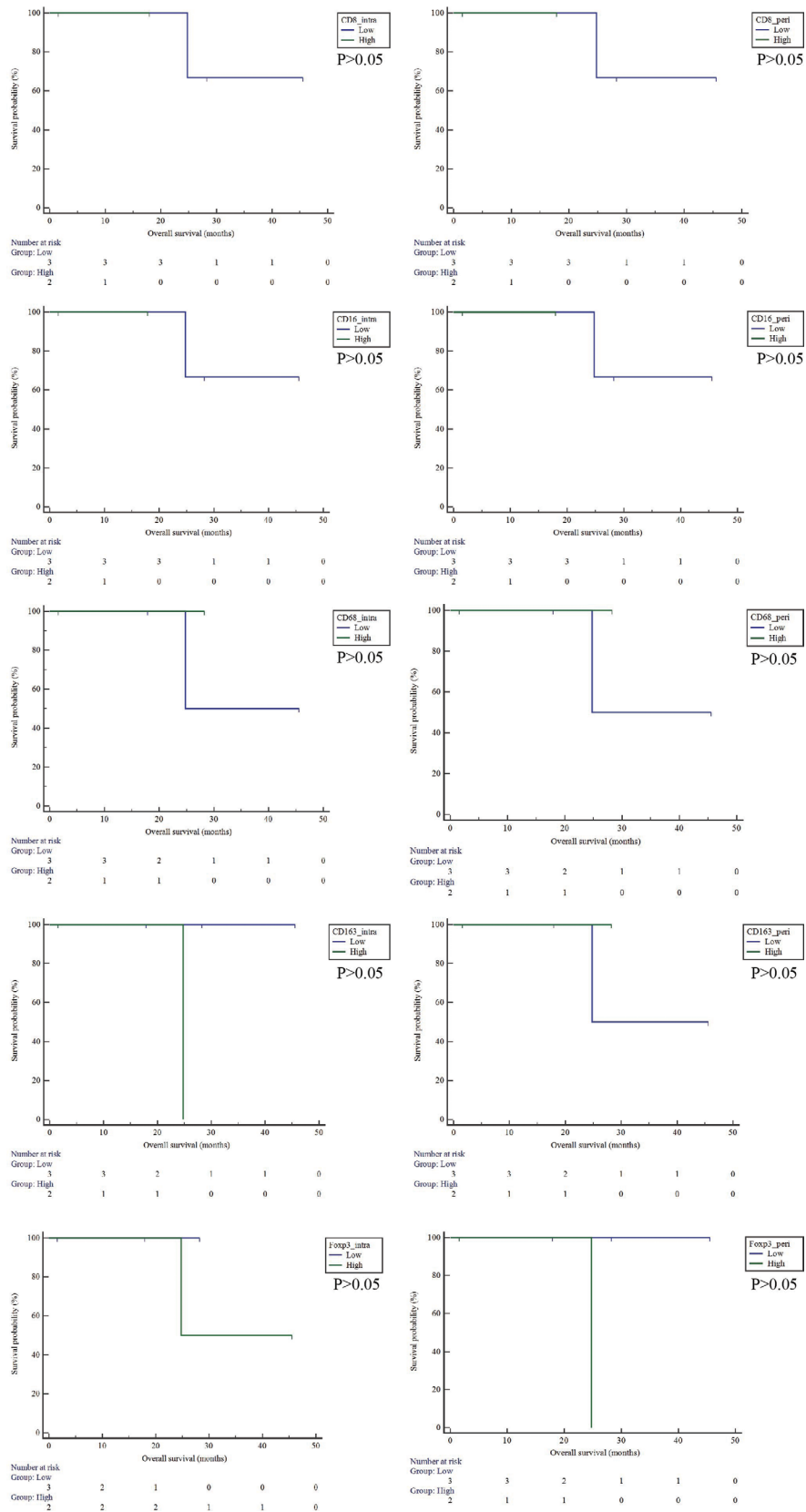


Figure S5 The relationship between the infiltration of immune cells and overall survival in SCC. SCC, squamous cell carcinoma.