

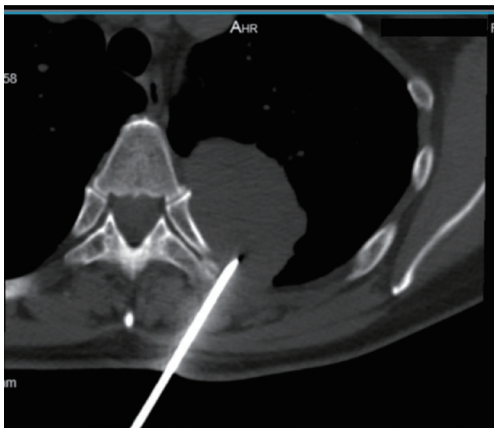Figure S1 Image of CT-guided biopsy.

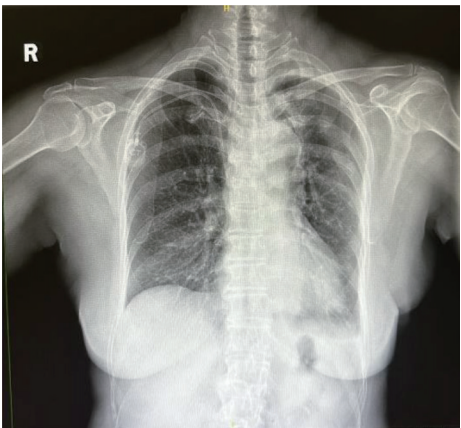


Figure S2 X-rays taken one month after surgery.

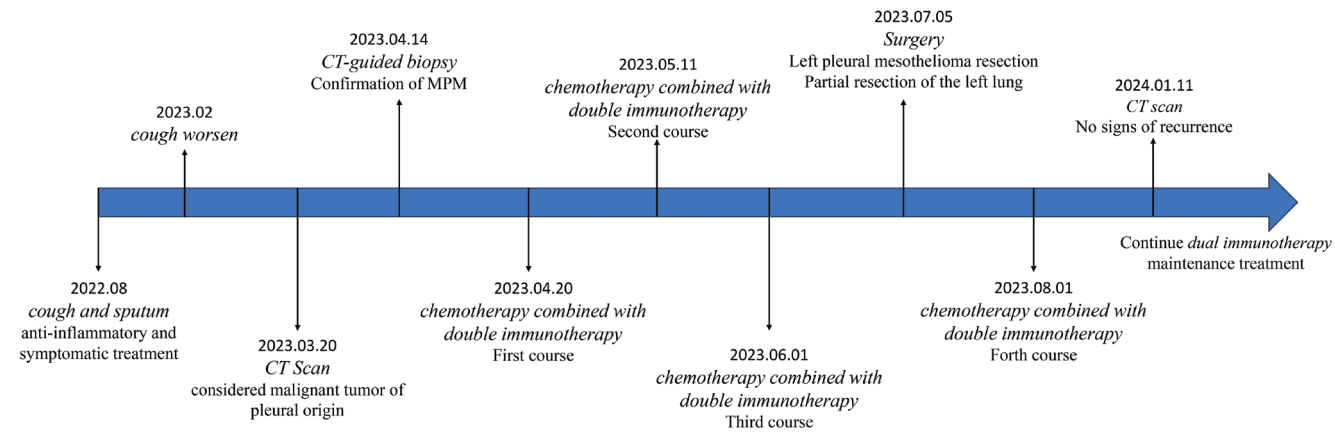


Figure S3 Schematics showing the treatment history of the patient.