

Clinical implication of *MEN1* mutation in surgically resected thymic carcinoid patients

Xiongfei Li^{1*}, Mingbiao Li^{1*}, Tao Shi^{2*}, Renwang Liu¹, Dian Ren¹, Fan Yang¹, Sen Wei¹, Gang Chen¹, Jun Chen^{1,3}, Song Xu^{1,3}

¹Department of Lung Cancer Surgery, ²Department of Pathology, ³Tianjin Key Laboratory of Lung Cancer Metastasis and Tumor Microenvironment, Lung Cancer Institute, Tianjin Medical University General Hospital, Tianjin 300052, China

*These authors contributed equally to this work.

Correspondence to: Jun Chen, MD, PhD and Song Xu, MD, PhD. Department of Lung Cancer Surgery, Lung Cancer Institute, Tianjin Medical University General Hospital, No. 154 Anshan Road, Heping District, Tianjin 300052, China. Email: huntercj2004@yahoo.com; xusong198@hotmail.com.

Abstract: Thymic carcinoid is a rare but very aggressive neuroendocrine tumour derived from the neuroendocrine system. Here we report a male patient with thymic atypical carcinoid. Though thymic carcinoid is relatively common, the gene sequencing profile was performed and the gene sequencing result indicated germline multiple endocrine neoplasia type 1 (*MEN1*) mutation and two somatic mutations on *MEN1* gene and no copy number variation or fusion events were detected. It is well-known that the mutation of *MEN1* is the typical manifestation of *MEN1* syndrome, which is an autosome dominant disease that includes varying combinations of more than 20 endocrine and non-endocrine tumors. In the English literature, 7 cases of solitary thymic carcinoid harboring somatic variants in *MEN1* are reported in the absence of other organs involvement as *MEN1* syndrome presents. We summarized the clinical features and prognosis of this rare thymic tumor.

Keywords: Multiple endocrine neoplasia type 1 (*MEN1*); thymic carcinoid; next generation sequencing (NGS); prognosis

Submitted Sep 20, 2017. Accepted for publication Jan 17, 2018. This article was updated on January 05, 2021.

The original version was available at: <http://dx.doi.org/10.21037/jtd.2018.01.127>

doi: 10.21037/jtd.2018.01.127

Introduction

Thymic carcinoid refers to a neuroendocrine tumour arising in the thymus, accounting for about 2–7% of anterior mediastinal masses (1,2). Approximately 40% of patients have Cushing syndrome as a result of adrenocorticotrophic hormone secretion by the tumour (1). Since the initial report of thymic carcinoid by Rosai and Higa in 1972 (3), about 200 cases of thymic carcinoid have been reported in English literature so far. We describe a 62-year-old male patient with surgically resected thymic carcinoid and mutations of *MEN1* gene were detected by next generation sequencing (NGS). Previous evidence indicates that thymic carcinoids occur in 1–5% of patients with multiple endocrine neoplasia type 1 (*MEN1*) syndrome and are a major cause of morbidity and mortality (4). We did a literature review and analyzed the clinicopathologic

characteristics of all thymic carcinoid patients with the initial manifestation of *MEN1* syndrome. All of thymic carcinoids patients with somatic mutation of *MEN1* gene had *MEN1* syndrome. Considering none of other organs involved and a negative family history of *MEN1* syndrome, our patient could not be diagnosed with *MEN1* syndrome at this moment. Based on the findings of our literature review, we proposed that somatic mutation test of *MEN1* gene and evaluation of other organs are recommended for thymic carcinoid patients. Moreover, close follow-up of thymic carcinoid patients with somatic mutation of *MEN1* gene is necessary and could help detect disease recurrence and metastases early.

Case presentation

A 62-year-old male patient was admitted to the hospital

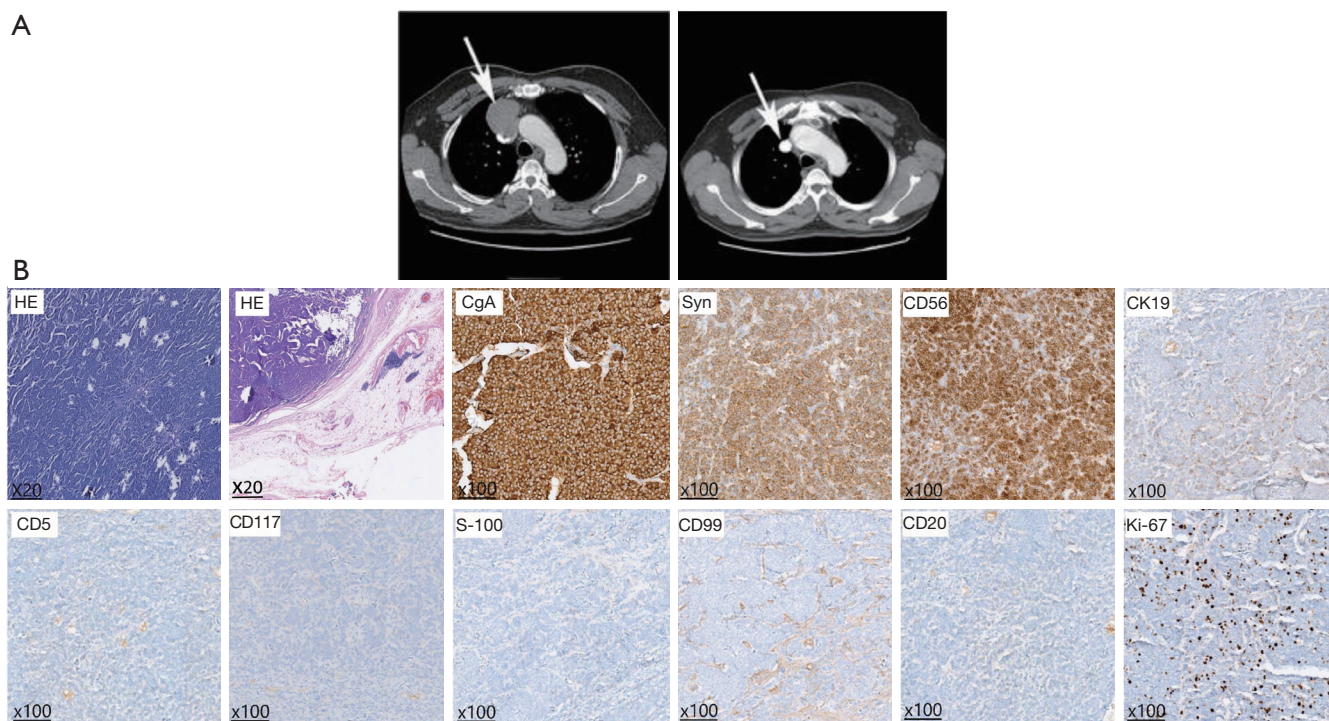


Figure 1 CT images and pathological stainings. (A) *Left*: preoperative CT image. Arrow indicates that anterior mediastinum invades the superior vena cava. *Right*: postoperative CT image. Arrow indicates artificial blood vessel reconstruction; (B) HE and IHC stainings. CT, computed tomography; HE, hematoxylin and eosin; IHC, immunohistochemistry; CgA, chromogranin A.

because of chest discomfort in June 2015. An enhanced chest computed tomography (CT) showed an anterior mediastinum mass invading superior vena cava, approximately 6 cm × 5 cm × 2 cm in size (*Figure 1A*). Positron emission tomography indicated the mass had an abnormal ¹⁸F-fludeoxyglucose (FDG) uptake and a preliminary diagnosis of malignant anterior mediastinum mass was given. Physical examination, laboratory evaluation, and radiological tests of other organs revealed no significant abnormalities. A resection of mediastinum mass together with systemic lymphadenectomy and artificial blood vessel reconstruction was performed using a midline approach through a sternotomy. Macroscopically, the mass was 5.5 cm × 4.5 cm × 2.2 cm with gray, soft and smooth section. Microscopically, postoperative hematoxylin and eosin (HE) staining showed thymic tissue, together with 2–4 nuclear mitosis per 10 HPF and focal necrosis. And immunohistochemistry (IHC) staining was positive for chromogranin A (CgA), Syn, CD56, CK19 and negative for CD5, CD117, S-100, CD99, CD20 with a Ki-67 index of 15% (*Figure 1B*). Through HE and IHC stainings, the

diagnosis of thymic atypical carcinoid was established. Postoperative CT showed clear lungs and artificial blood vessels with smooth blood flow (*Figure 1A*). The patient recovered well and was discharged favorably. The patient refused to receive any postoperative therapy except close follow-up. Until 20 months postoperatively, the patient was symptom-free and had no evidences of local and systematic abnormalities.

To explore the underlying mechanisms, a genetic mutation profiling of 295 cancer related genes was performed by NGS (OncoScreen™ 295 genes, Burning Rock Dx, Guangzhou, China, *Figure S1*). The gene sequencing result indicated germline *MEN1* mutation and two somatic mutations on *MEN1* gene (One nonsense mutation in exon 10 with 45.6% frequency and one missense mutation in exon 6 with 41.9% frequency) and no copy number variation or fusion events were detected (*Figure 2A*). We further point out somatic mutation locus of our patient on MutationMap together with all *MEN1* mutations from the cancer genome atlas (TCGA) database (*Figure 2B*). We also retrieved the clinicopathologic

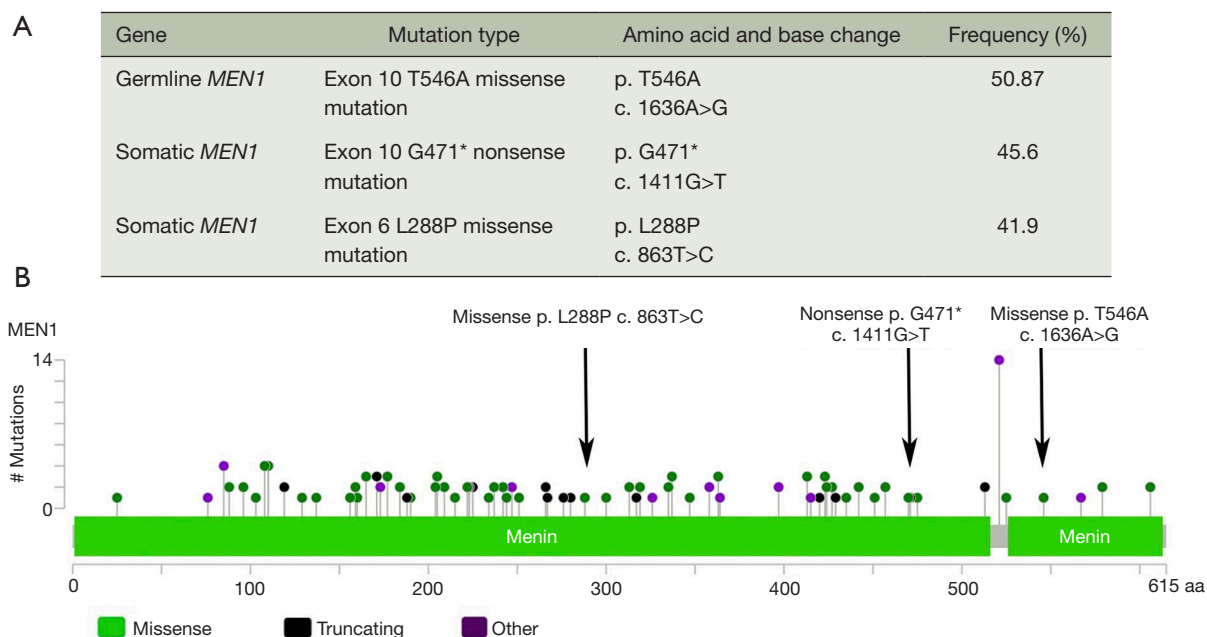


Figure 2 Gene mutation analysis. (A) NGS analysis detected germline and somatic *MEN1* mutations; (B) MutationMap of *MEN1* mutation from TCGA database. NGS, next generation sequencing; *MEN1*, multiple endocrine neoplasia type 1; TCGA, the cancer genome atlas.

characteristics of all thymic carcinoid patients with the initial manifestation of *MEN1* syndrome in previous published literatures from PubMed.

Discussion

MEN1 gene mutations can be identified in 70–95% of *MEN1* patients. *MEN1* follows Knudson's "two-hit" model for tumor suppressor gene carcinogenesis. The first hit is a heterozygous *MEN1* germline mutation, and the second hit is a *MEN1* somatic mutation and gives cells the survival advantage needed for tumor development (5). The thymic carcinoid of our case might be caused by the twice mutations on *MEN1* gene according to Knudson's "two-hit" model. Carcinoid tumors are estimated to occur in about 10% of *MEN1* patients, and thymic carcinoids were reported be more aggressive with a poor prognosis of 10-year overall survival rate about 25–36% in the literature (4). Thymic carcinoids are more prevalent in males than in females and most patients are clinically silent.

In literature, we found six patients exhibited thymic carcinoid as the initial manifestation of *MEN1* syndrome (4,6-10). We summarized the clinical features of these cases (Table 1). We confirmed that a higher percentage of thymic carcinoids can occur in men which might the effect of sex

hormone promoting the proliferation and maturation of thymocyte in *MEN1* syndrome (Table 1) (11). The age of patients was young, ranging from 23 to 53 with a median age is 36.5, which might indicate the aggressive nature of disease. Gibril *et al.* reported that about 1/3 *MEN1* related thymic carcinoid patients were asymptomatic or only have non-specific symptoms when they had already local invasion or metastases at the time of initial diagnosis (12). The mutations of *MEN1* are also listed in the Table 1. The types of mutations include duplication, insertion, deletion, frameshift and nonsense mutation, which occur in exon 2, 3, 5, 9 and 10. Among all the mutations, the mutations in exon10 occur three times which is the same for our case.

Although *MEN1* related thymic carcinoid patients only account for less than 5 percentage of all the *MEN1* patients, they were associated with an increased mortality and a poorer prognosis due to the more aggressive nature and potential for metastasis (13-15). Early and correct diagnosis is particularly important for thymic carcinoid patients with *MEN1* syndrome. In our case, the patient was diagnosed as thymic atypical carcinoid with mutation of *MEN1* gene. But he had none of other organs involvement at the time of diagnosis and a negative family history of *MEN1* syndrome. However, based on the findings of our literature review, we have to bear in mind that this thymic carcinoid patient

Table 1 Literature review of patients with thymic carcinoid as the initial manifestation of MEN1 syndrome

Reference	Age/sex	Smoking	Type of <i>MEN1</i> mutation	Other organs involvement	Family history of MEN1	MEN1 syndrome diagnosis	Follow-up (months)	Status
Christakis <i>et al.</i> (4)	23/M	No	Duplication and insertion mutation of exons 9, 10	None	NK	Yes	84	Dead
Hasani-Ranjbar <i>et al.</i> (6)	29/M	No	Deletion mutation exon 10	PH/PA	Yes	Yes	24	Alive
Kikuchi <i>et al.</i> (7)	53/M	NK	Deletion mutation exon 5	Parathyroid tumor/PET	No	Yes	36	Alive
Ghazi <i>et al.</i> (8)	44/M	NK	Frameshift mutation exon 10	PA/PH	Yes	Yes	49	Dead
Ferolla <i>et al.</i> (9)	47/M	Yes	Frameshift mutation exon 2	PH	Yes	Yes	36	Dead
Boix <i>et al.</i> (10)	25/F	NK	Nonsense mutation exon 3	None	Yes	Yes	111	Dead

M, male; F, female; NK, not known; PH, parathyroid hyperplasia; PA, pituitary adenoma; PET, pancreatic endocrine tumor; MEN1, multiple endocrine neoplasia type 1.

with *MEN1* somatic mutation might develop metachronous neoplasias.

Therefore, we proposed that gene mutation test of *MEN1* and evaluation of other organs are recommended for thymic carcinoid patients. Moreover, close follow-up of thymic carcinoid patients with somatic mutation of *MEN1* gene is necessary and could help detect disease recurrence and metastases early.

Conclusions

Thymic carcinoid patients with *MEN1* gene mutation are rare. Literature review shows that a much higher percentage of *MEN1* gene mutation related thymic carcinoids can occur in men and develop synchronous or metachronous neoplasia in other organs. Therefore, for patients with thymic carcinoid, testing of *MEN1* gene mutation is recommended. In addition, systematic evaluations and close follow-up are necessary for the thymic carcinoid patients with *MEN1* mutation because of the highly possible involvement of other organs and development of MEN1 syndrome.

Acknowledgements

Funding: This work was financially supported by grants from the National Natural Science Foundation of China (81772464, 81773207), the Science and Technology Support

Key Program of Tianjin (17YFZCSY00840), Tianjin Key Project of Natural Science Foundation (16JCZDJC34200, 16PTSJJC00160, 17JCZDJC36200).

Footnote

Conflicts of Interests: The authors have no conflicts of interest to declare.

Informed Consent: The patient granted written informed consent for publication of this manuscript and the accompanying images.

References

- Recuero Díaz JL, Embún Flor R, Menal Muñoz P, et al. Thymic carcinoid associated with multiple endocrine neoplasia syndrome type I. *Arch Bronconeumol* 2013;49:122-5.
- Dixon JL, Borgaonkar SP, Patel AK, et al. Thymic neuroendocrine carcinoma producing ectopic adrenocorticotrophic hormone and Cushing's syndrome. *Ann Thorac Surg* 2013;96:e81-3.
- Rosai J, Higa E. Mediastinal endocrine neoplasm, of probable thymic origin, related to carcinoid tumor. *Clinicopathologic study of 8 cases.* *Cancer* 1972;29:1061-74.
- Christakis I, Qiu W, Silva Figueroa AM, et al. Clinical Features, Treatments, and Outcomes of Patients with

- Thymic Carcinoids and Multiple Endocrine Neoplasia Type 1 Syndrome at MD Anderson Cancer Center. *Horm Cancer* 2016;7:279-87.
5. Marx SJ, Agarwal SK, Kester MB, et al. Germline and somatic mutation of the gene for multiple endocrine neoplasia type 1 (MEN1). *J Intern Med* 1998;243:447-53.
 6. Hasani-Ranjbar S, Rahmanian M, Ebrahim-Habibi A, et al. Ectopic Cushing syndrome associated with thymic carcinoid tumor as the first presentation of MEN1 syndrome-report of a family with MEN1 gene mutation. *Fam Cancer* 2014;13:267-72.
 7. Kikuchi R, Mino N, Okamoto T, et al. Simultaneous double thymic carcinoids: a rare initial manifestation of multiple endocrine neoplasia type 1. *Gen Thorac Cardiovasc Surg* 2011;59:68-72.
 8. Ghazi AA, Dezfooli AA, Mohamadi F, et al. Cushing syndrome secondary to a thymic carcinoid tumor due to multiple endocrine neoplasia type 1. *Endocr Pract* 2011;17:e92-6.
 9. Ferolla P, Falchetti A, Filosso P, et al. Thymic neuroendocrine carcinoma (carcinoid) in multiple endocrine neoplasia type 1 syndrome: the Italian series. *J Clin Endocrinol Metab* 2005;90:2603-9.
 10. Boix E, Picó A, Pinedo R, et al. Ectopic growth hormone-releasing hormone secretion by thymic carcinoid tumour. *Clin Endocrinol (Oxf)* 2002;57:131-4.
 11. Seiki K, Sakabe K. Sex hormones and the thymus in relation to thymocyte proliferation and maturation. *Arch Histol Cytol* 1997;60:29-38.
 12. Gibril F, Chen YJ, Schrupp DS, et al. Prospective study of thymic carcinoids in patients with multiple endocrine neoplasia type 1. *J Clin Endocrinol Metab* 2003;88:1066-81.
 13. Ito T, Jensen RT. Imaging in multiple endocrine neoplasia type 1: recent studies show enhanced sensitivities but increased controversies. *Int J Endocr Oncol* 2016;3:53-66.
 14. Goudet P, Murat A, Binquet C, et al. Risk factors and causes of death in MEN1 disease. A GTE (Groupe d'Etude des Tumeurs Endocrines) cohort study among 758 patients. *World J Surg* 2010;34:249-55.
 15. Brandi ML, Gagel RF, Angeli A, et al. Guidelines for diagnosis and therapy of MEN type 1 and type 2. *J Clin Endocrinol Metab* 2001;86:5658-71.

Cite this article as: Li X, Li M, Shi T, Liu R, Ren D, Yang F, Wei S, Chen G, Chen J, Xu S. Clinical implication of *MEN1* mutation in surgically resected thymic carcinoid patients. *J Thorac Dis* 2018;10(2):E125-E129. doi: 10.21037/jtd.2018.01.127